


3rd Annual
Joseph W. Howe
Oration in Diagnostic Imaging



"I Have Rheumatoid Arthritis...Now What?"

**Sharon A. Jaeger, D.C., D.A.C.B.R., F.I.C.C.
Private Chiropractic and Radiology Practice
Chatsworth, California**



Dr. Joseph Howe with his parents Drs. Mabel and Lawrence Howe



Dr. Joseph Howe with his beautiful wife Dee on their wedding day



**Dr. Joseph Howe with his beautiful wife Dee with their children (clockwise from left)
Mindy, Steve, Holly, Dan, Nancy and Jaynan (sitting on daddy's lap)**

Rheumatoid Arthritis

- Generalized connective tissue disorder
 - Involves most systems of body
- Unknown etiology
- Probably autoimmune
- Causing synovial hypertrophy and hyperplasia
- Progressive nature and bilaterality are hallmarks

Rheumatoid Arthritis

- Clinically

- Symptoms begin around 20 - 60 yrs
- 3:1 more commonly female until 40 yrs old then becomes 1:1
- Signs and symptoms begin in the hand usually at the metacarpophalangeal and interphalangeal joints

Rheumatoid Arthritis

- Clinically

- Spine is rarely involved until later in condition
- This is different in juvenile R.A.
- Fatigue, malaise, muscle weakness and fever are also seen

Rheumatoid Arthritis

- Laboratory

- Anemia (normochromic & normocytic)
- Increased ESR
- Rheumatoid factor present in about 70%
- This is **NOT** specific for R.A

New Serologic Tests

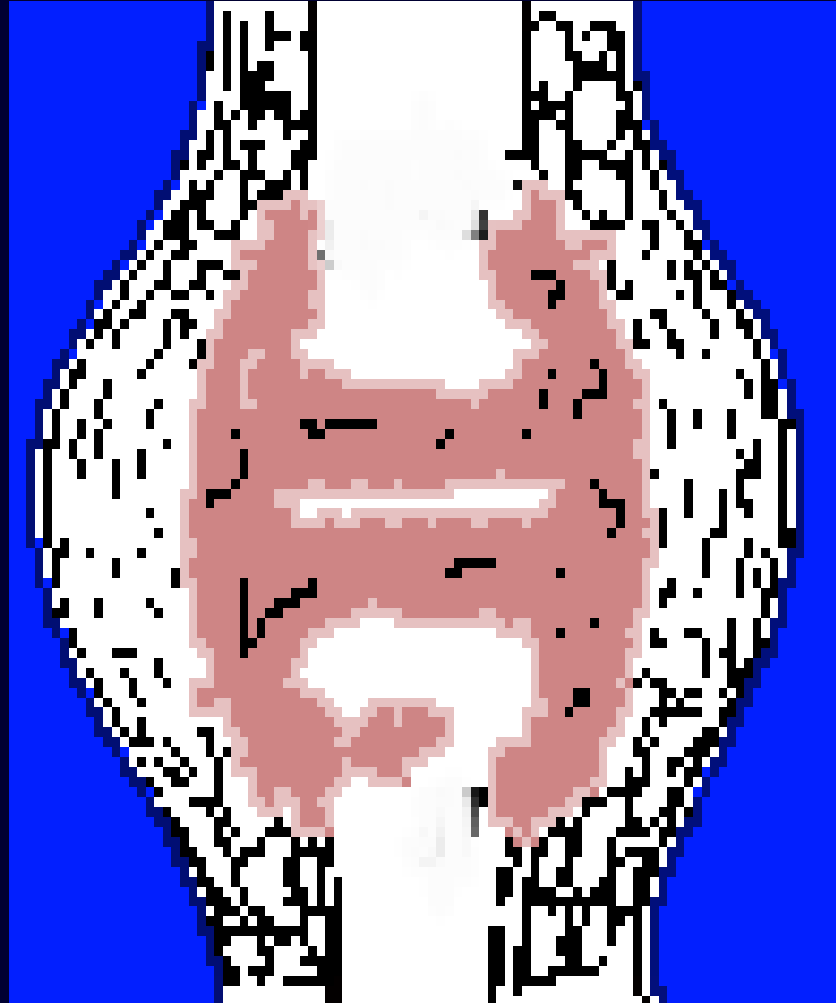
- Test for the presence of anti-citrullinated protein antibodies (ACPAs)
- These are positive in only 67% of all RA cases but are rarely positive if RA is not present giving it around 95% specificity

Rheumatoid Arthritis

- Pathological
 - Synovial hyperplasia and hypertrophy invade the joint space
 - Synovial hypertrophy (*pannus*) attacks the "bare areas"
 - Bursae contain similar tissue to synovial joints and hypertrophy occurs in these locations also

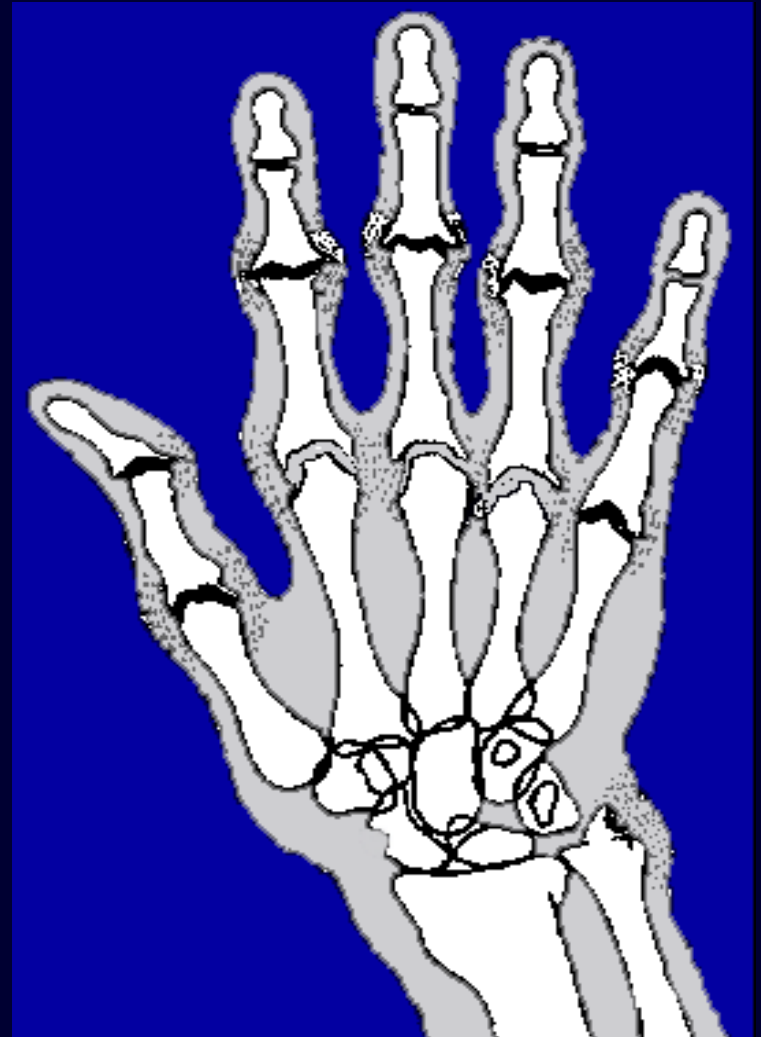
Rheumatoid Arthritis

- Pathological
 - Pannus attacks synovial cartilage and bone at the "bare areas"
 - Will not see decreased joint space early but will see periarticular erosion ("rat bite erosion")



Rheumatoid Arthritis

- Radiographic
 - Bilateral symmetry
 - Soft tissue swelling
 - Juxta-articular osteopenia
 - Uniform loss of joint space
 - Marginal erosions ("rat bite erosions")
 - Pseudocyst formation
 - Deformity




Early Radiographic Signs

- Usually the hands and feet are x-rayed in patients with polyarthritis
- There may be no changes in the early stages
- Juxta-articular osteopenia
- Soft tissue swelling
- Erosions may be noted; often the ulnar styloid process is the first site

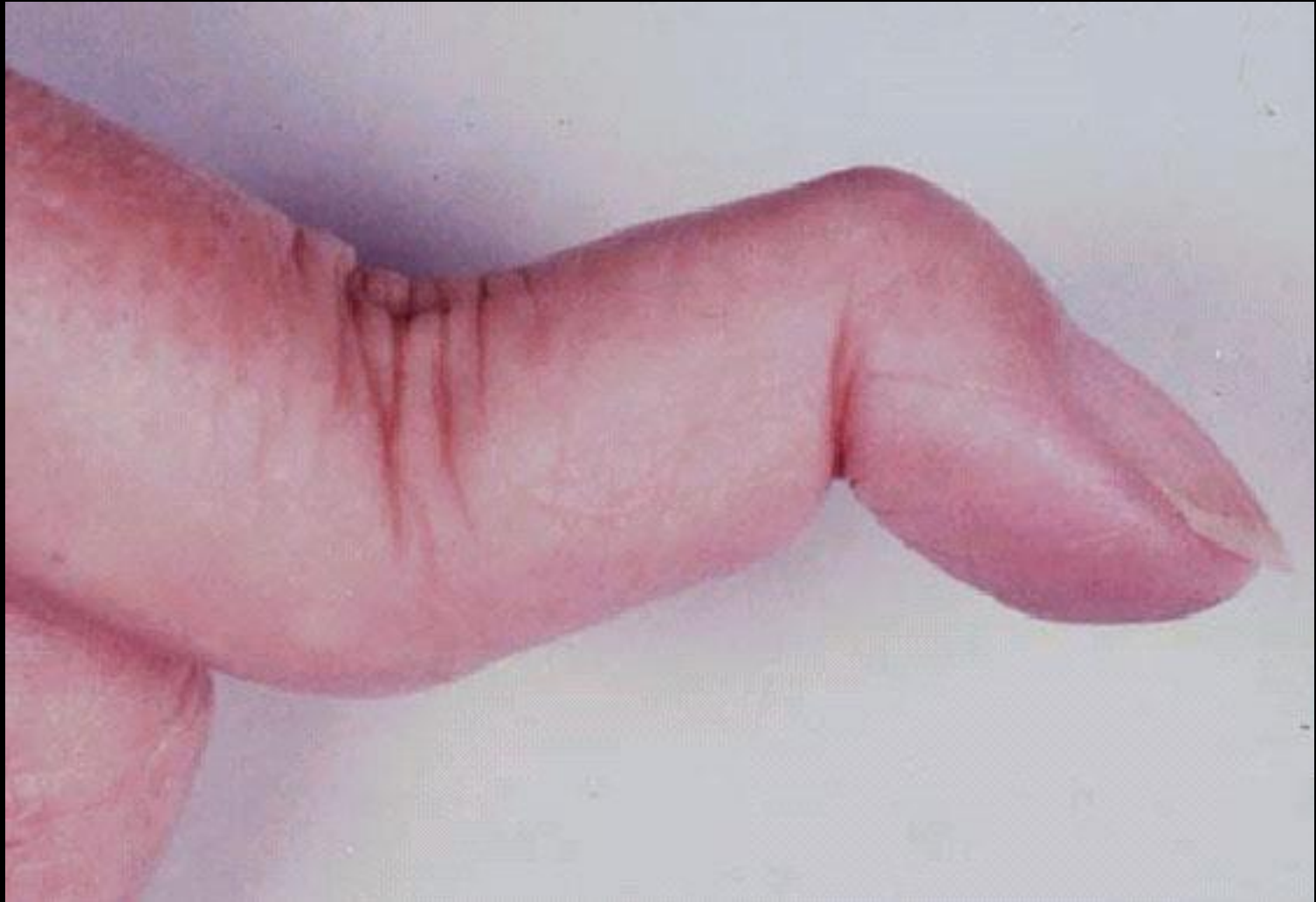Rheumatoid Arthritis

- Other areas of involvement
 - All bursa behave like synovial joints
 - Spontaneous tendon and ligament avulsions
 - Instability
 - Deformities

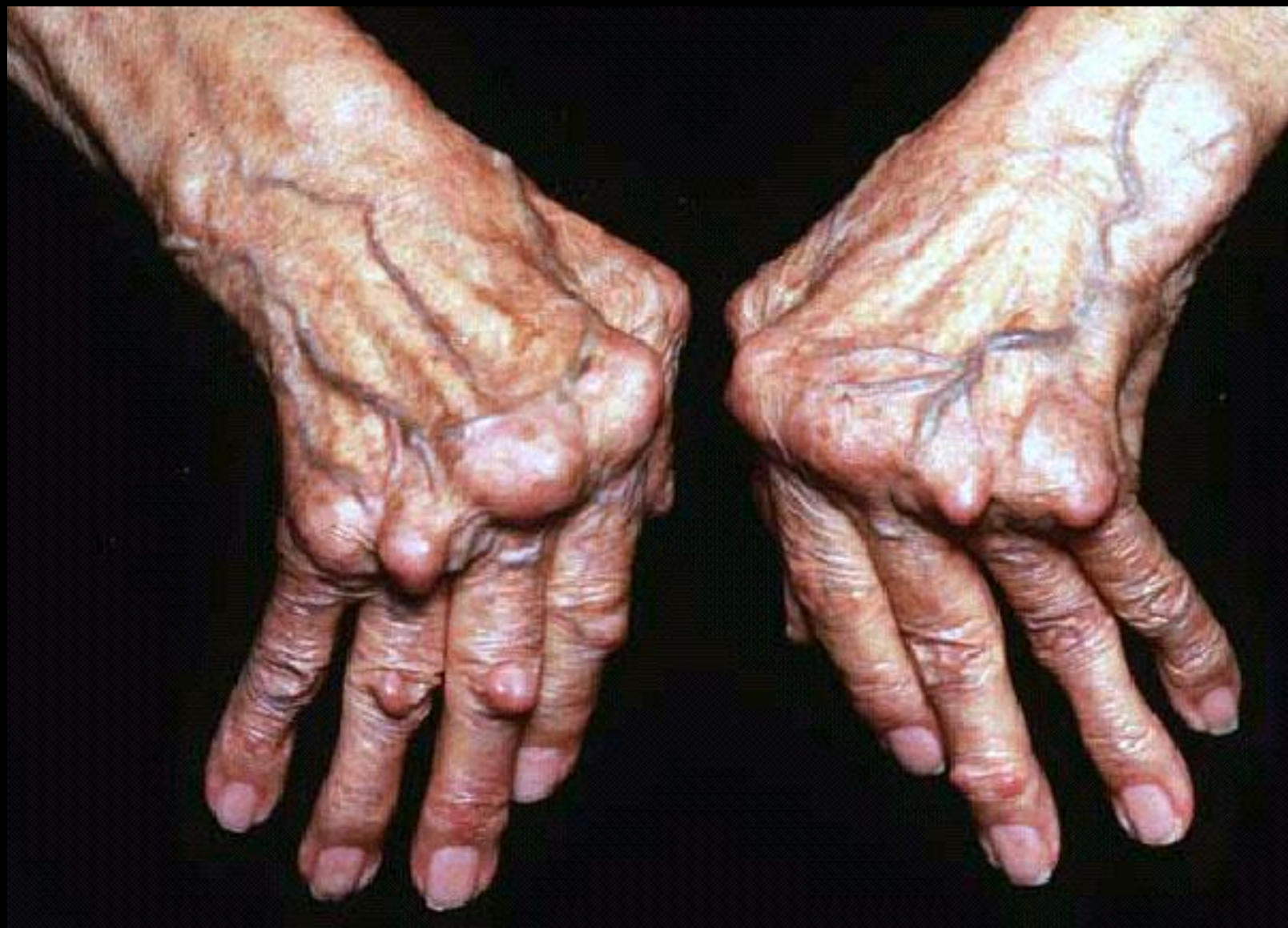

Boutonniere

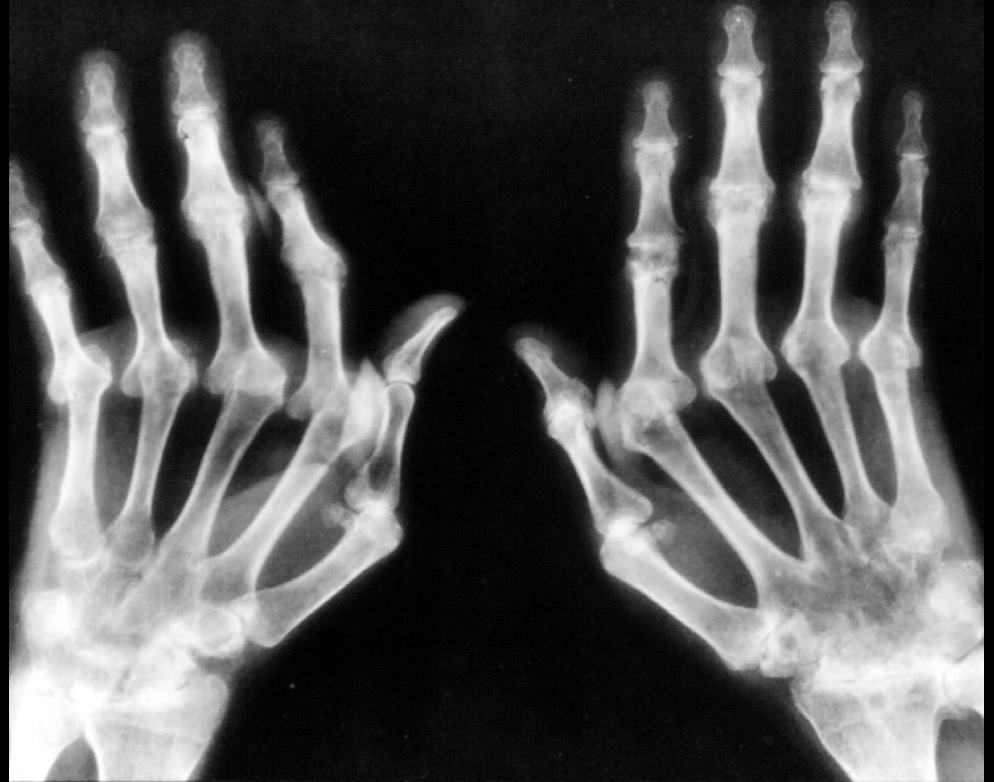
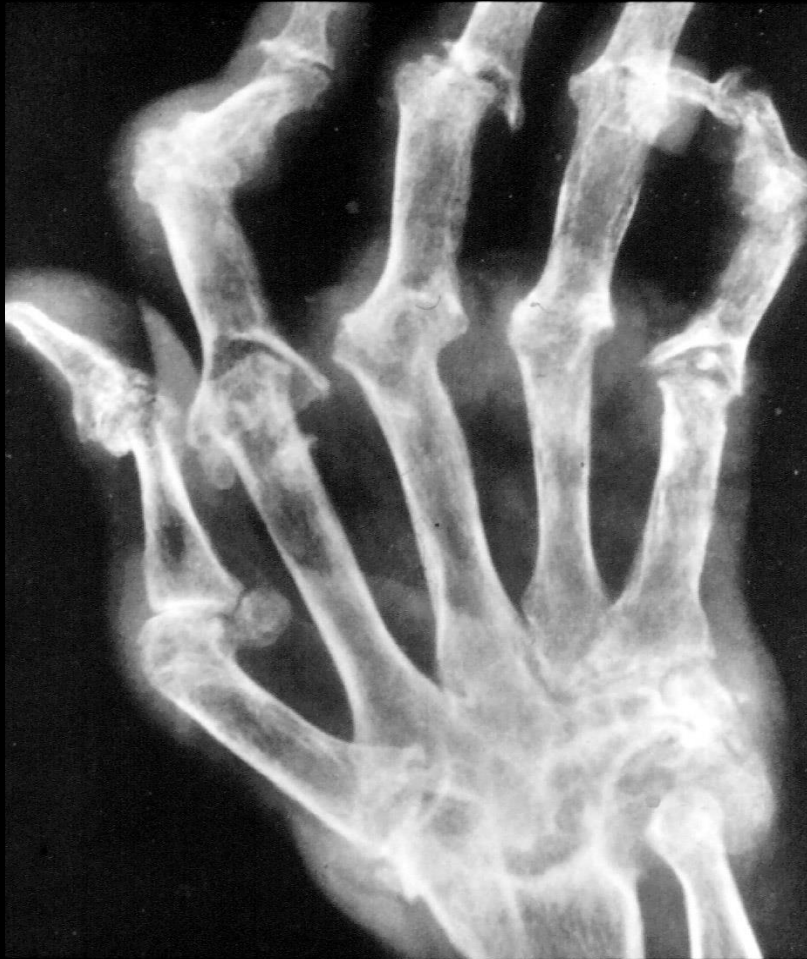Swan neck



Swan neck

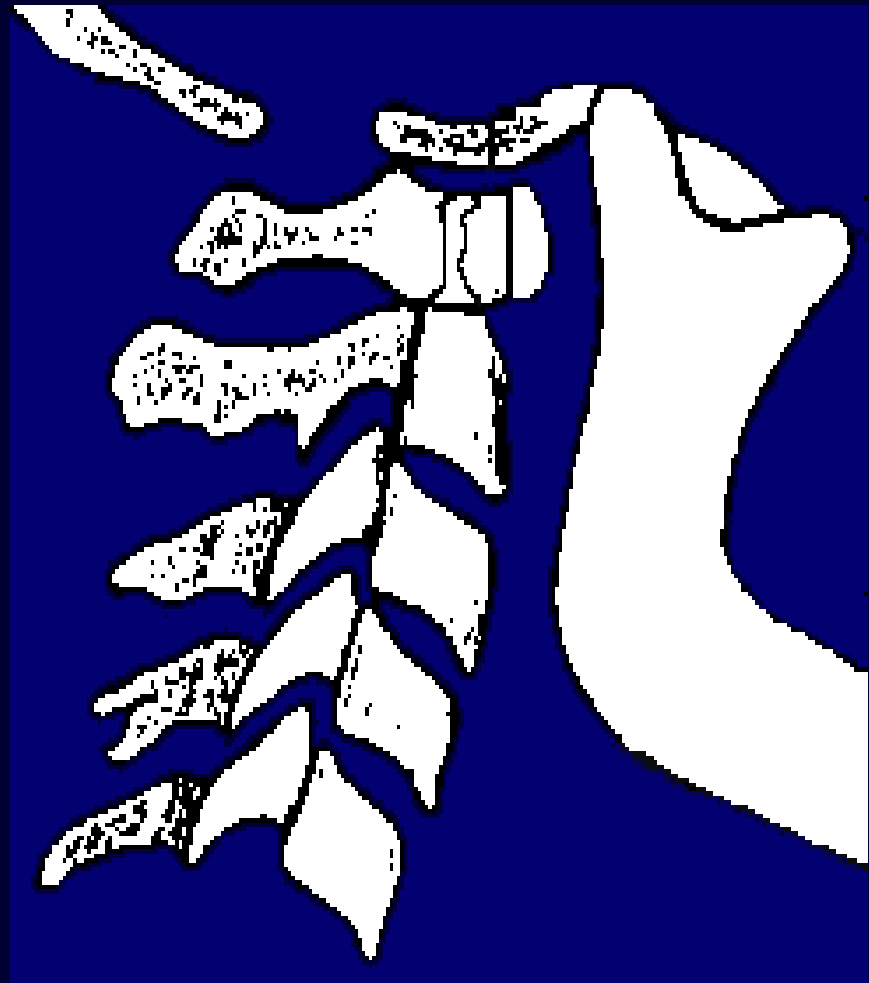


Rheumatoid Arthritis

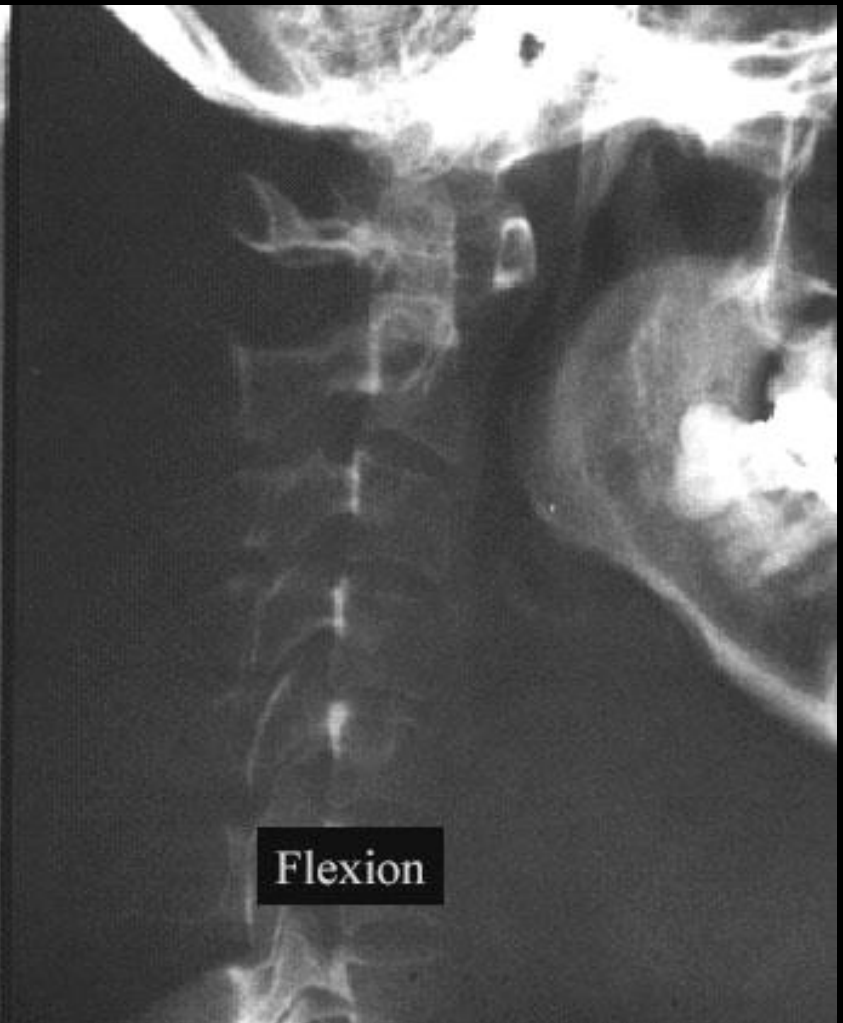
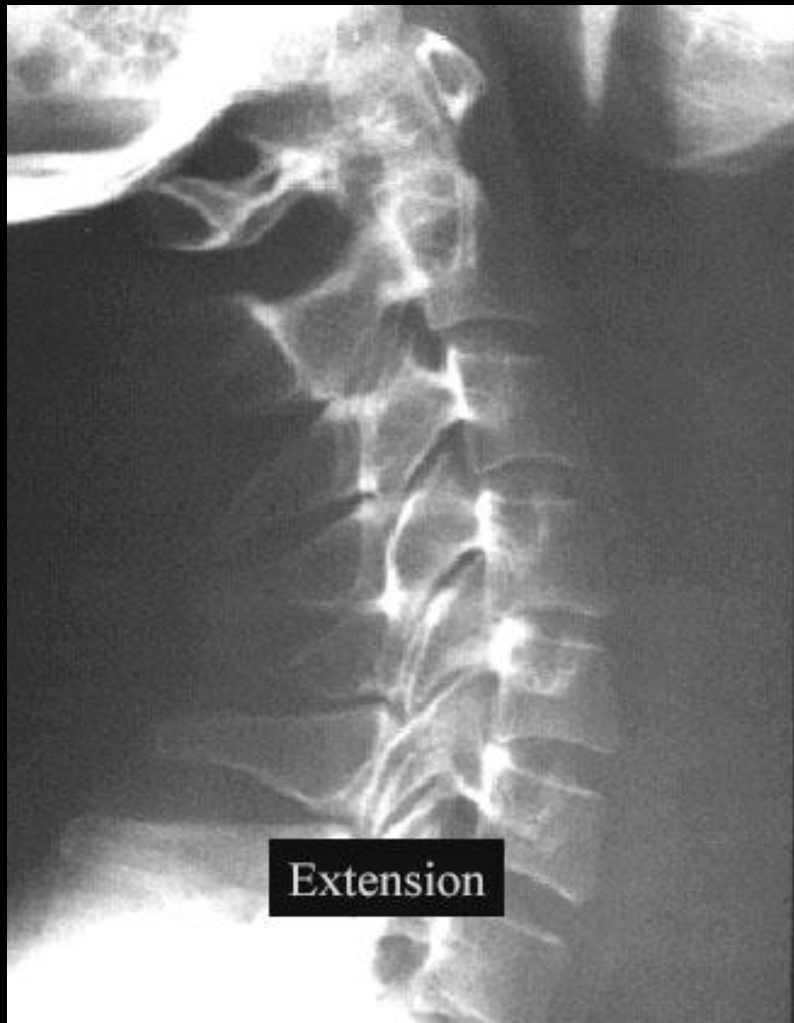
Spine Involvement

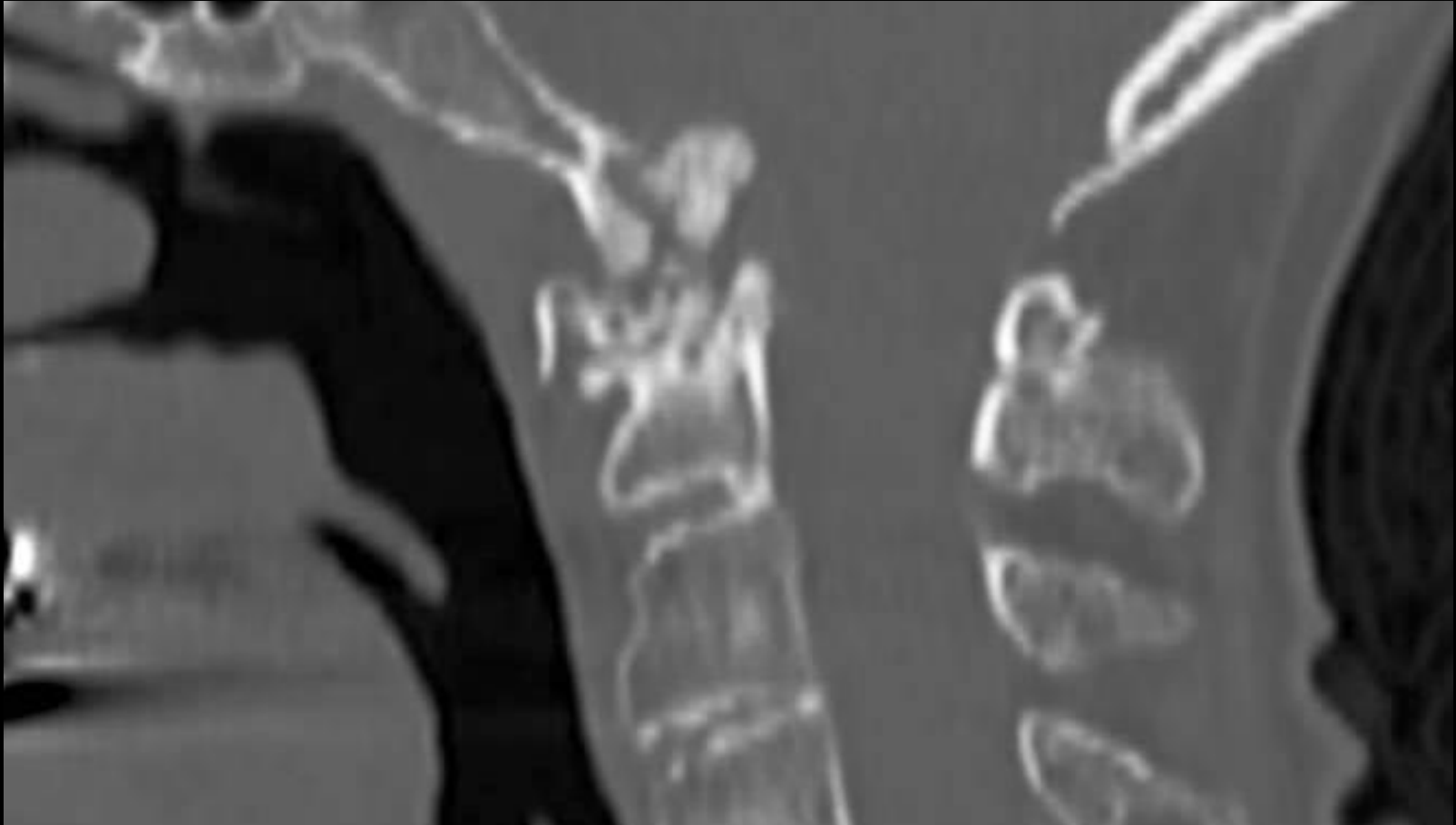
- Cervical spine instability with occipital subluxation
- Degenerative changes at several levels in cervical spine



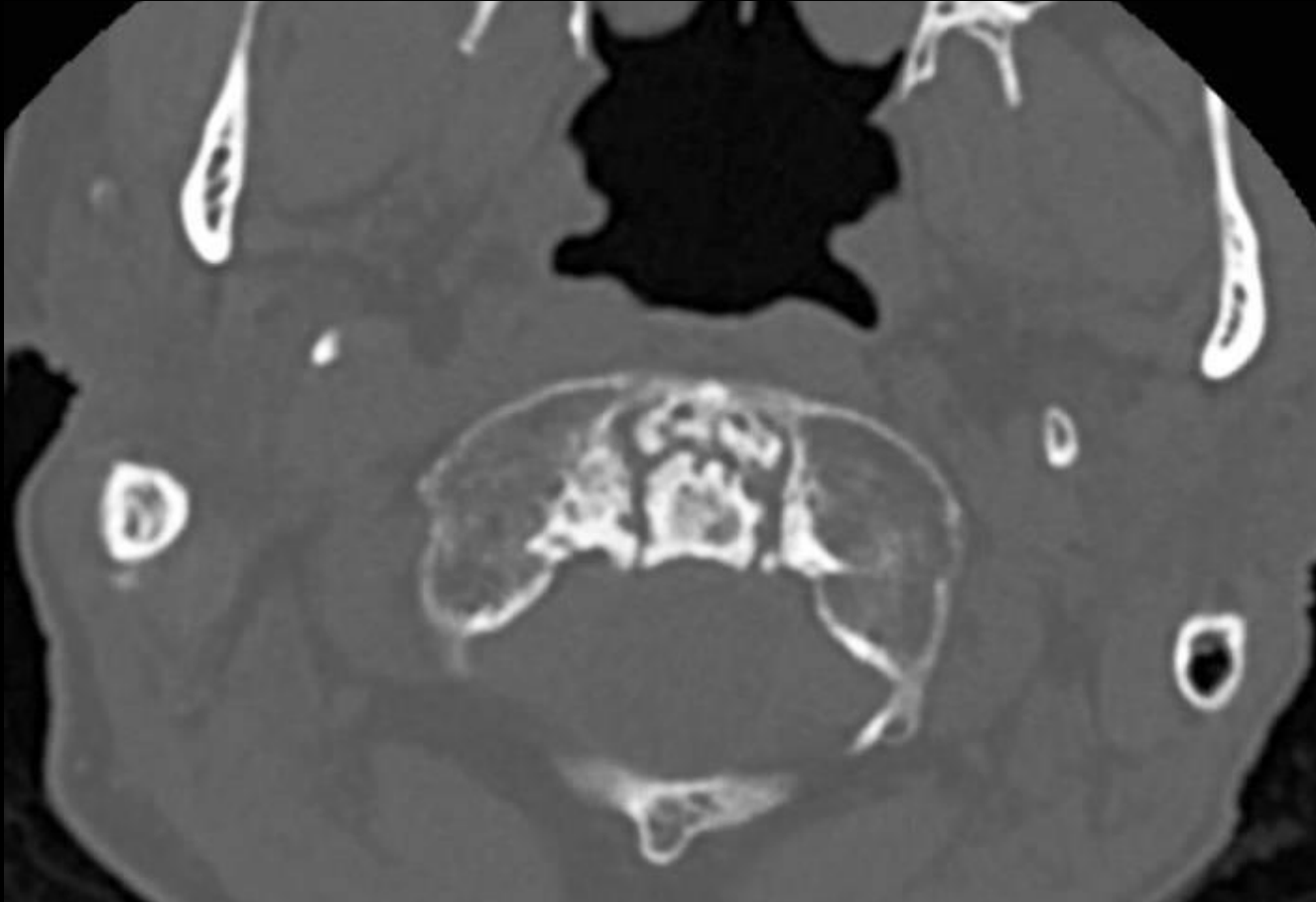
Rheumatoid Arthritis



Rheumatoid Arthritis



Rheumatoid Arthritis





Dr. Joseph Howe in the first post-graduate course in chiropractic radiology



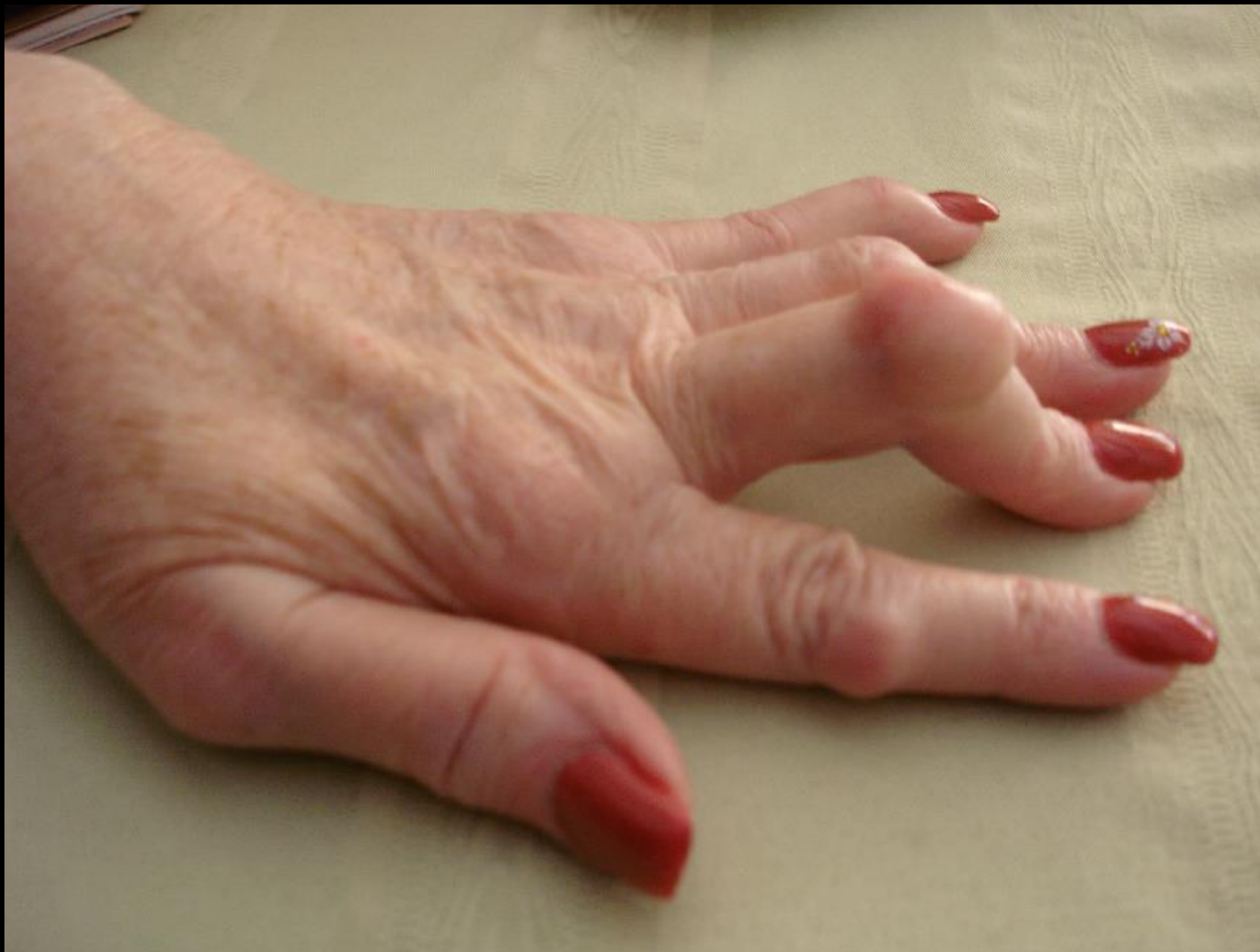1972 American Chiropractic Board of Radiology (ACBR)
Drs. Doug Ray, Leo Wunsch, Don Harrison, Mike Giammarino and Joseph Howe

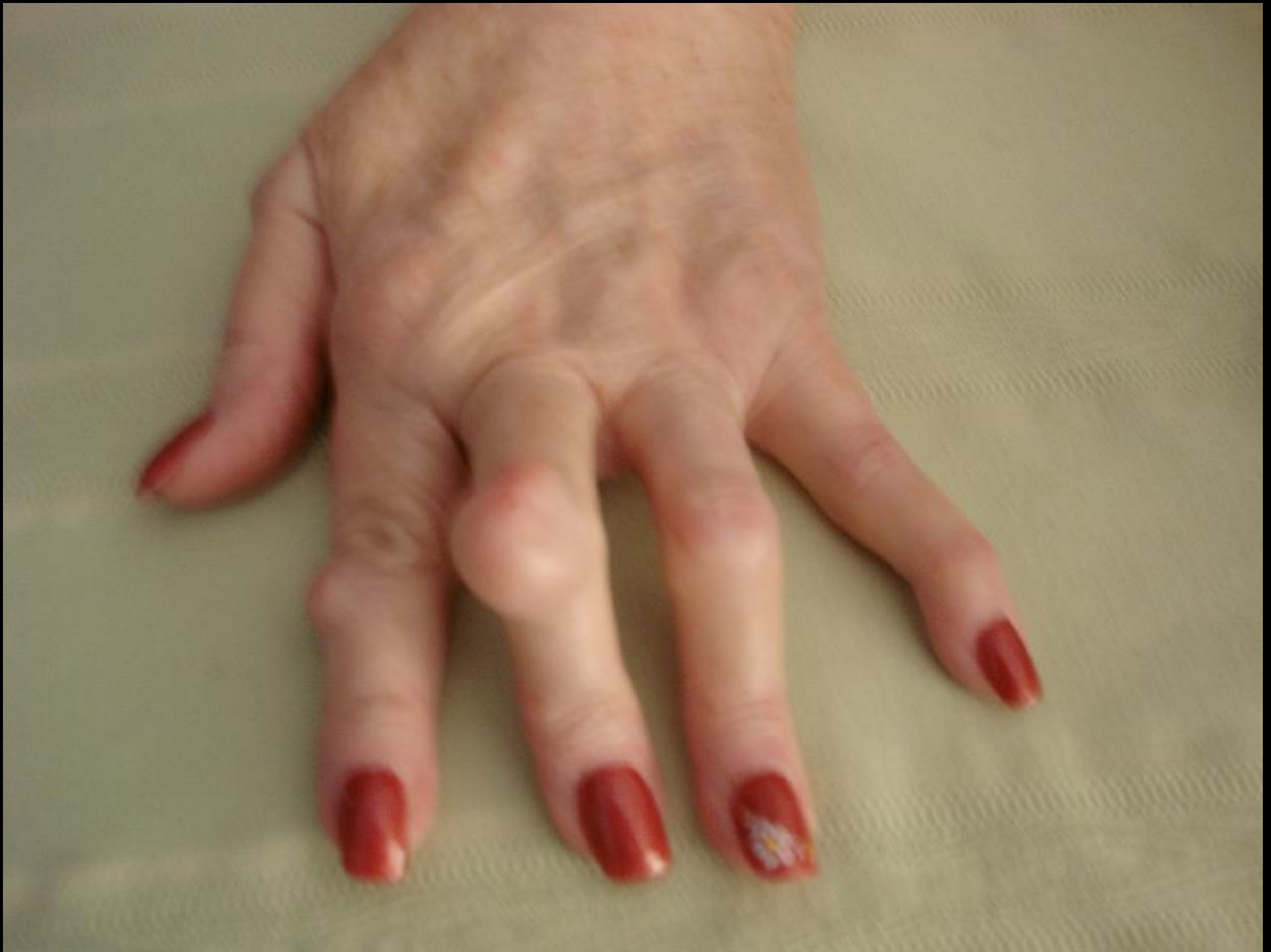

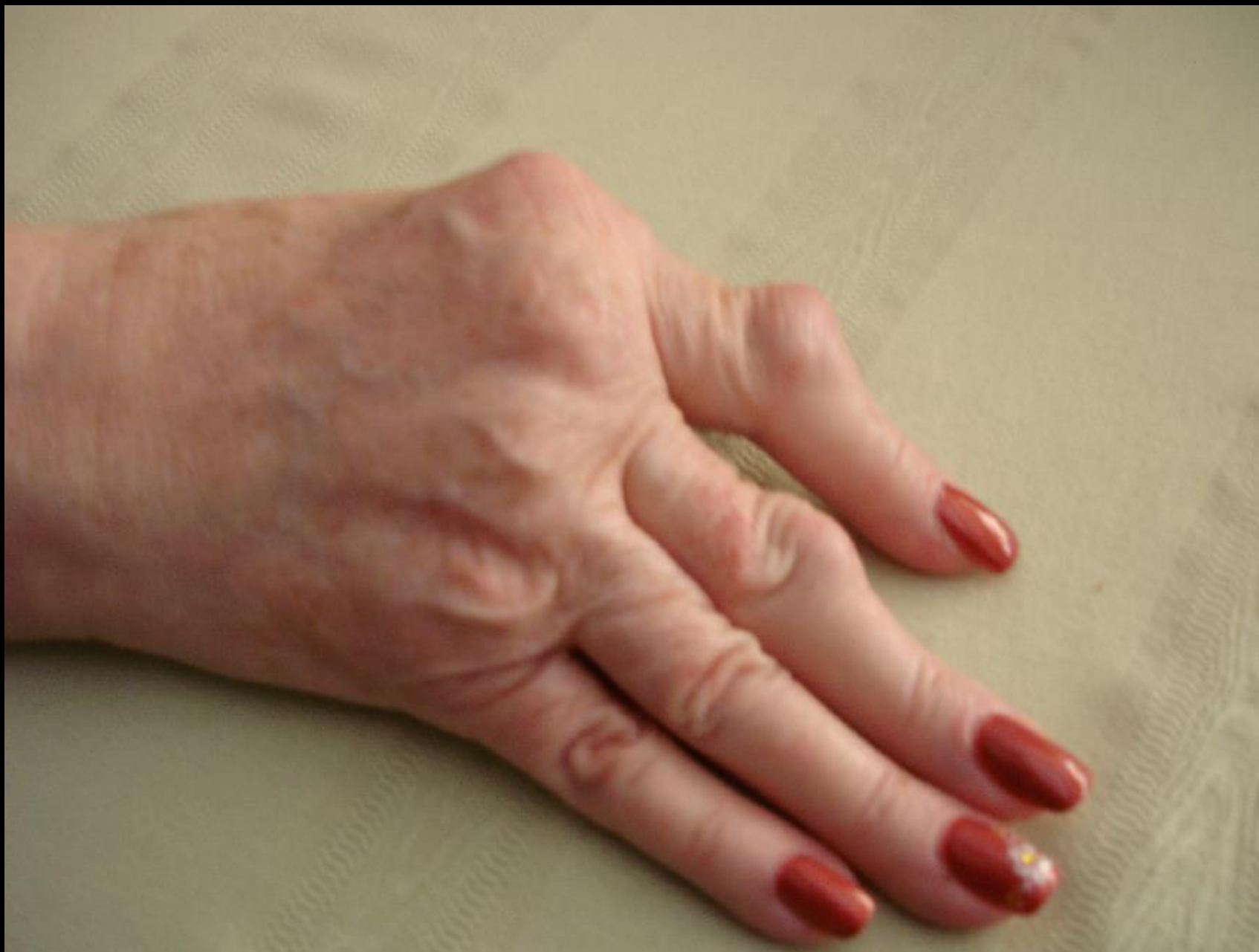Drs. Joseph Howe, Reed Phillips and Joseph Janse with their beautiful wives

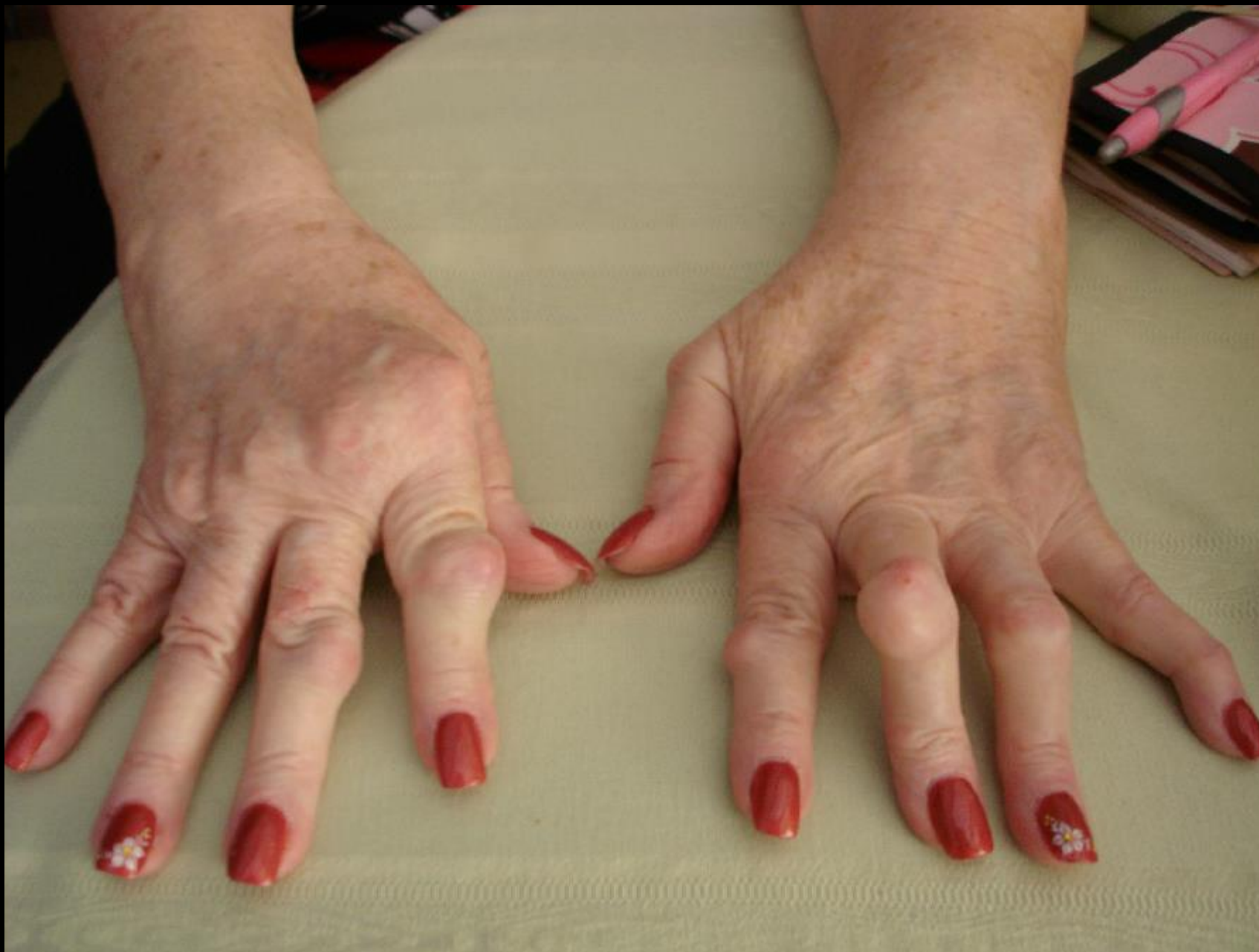Sheila's Story

- Age of onset 43
- Started in her left middle finger which became very sore and swollen then became red, hot and stiff
- Has had bilateral total knee replacements
 - Both lungs collapsed shortly thereafter
 - She was prescribed Coumadin
- Has chosen to have no further surgeries

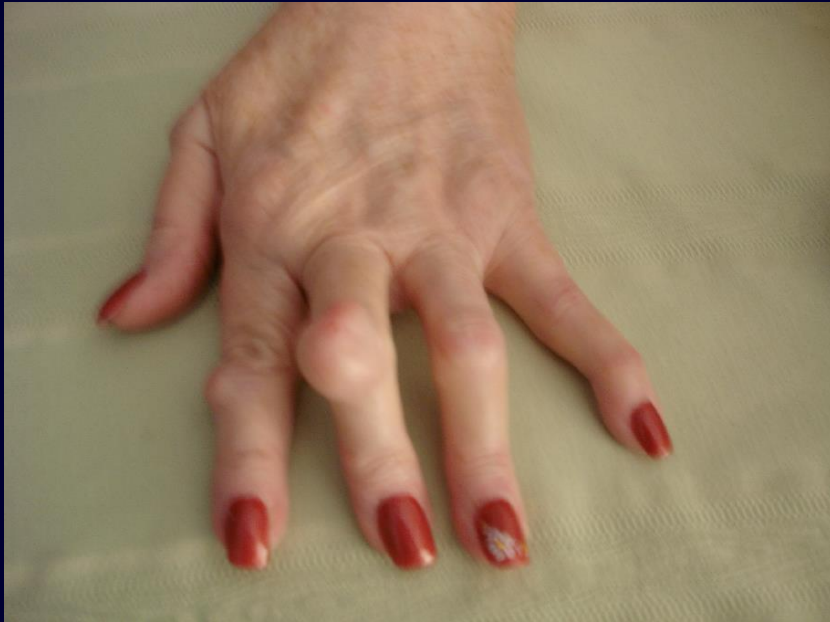







Sheila's Story




- Cannot control her 4th and 5th digits
- She has responded to methotrexate and more recently to Enbrel injections
- If she travels she is usually placed on prednisone
- Now also takes omega 3 fish oil



American Chiropractic College of Radiology (ACCR) members



Drs. Terry Yochum, Joseph Howe and William "Bill" Litterer



Drs. Joseph Howe, Sheri Jaeger, Donald Resnick and Lindsay Rowe

Helen's Story

- Presented with swelling of her fingers that became very red and hot
- Lab work determined that she had RA
- Her case was not typical
- She had pitting of her nails and a scalp rash (these findings had been present since high school)
- A biopsy was done of her scalp
- She was diagnosed with psoriasis

Psoriatic Arthritis

- Arthropathy associated with psoriasis
- Occurs in about 15% of patients with psoriasis
- Similar to R.A. except seronegative
- No sex preference for involvement

Psoriatic Arthritis

- **Clinical presentation**

- **Age range usually 20 - 40 yrs**
- **May or may not have skin manifestations**
- **Highest correlation is presence of nail changes**
- **Soft tissue swelling ("sausage digit")**
- **HLA-B27 antigen in up to 75% with sacroiliac involvement**

Psoriatic Arthritis

- Radiographic presentation
 - Affects hands, spine and sacroiliac joints primarily
 - Pannus formation present
 - Enthesopathy
 - Fibrous deposition within joint can lead to ankylosis
 - No hyperemia therefore no juxta-articular osteopenia

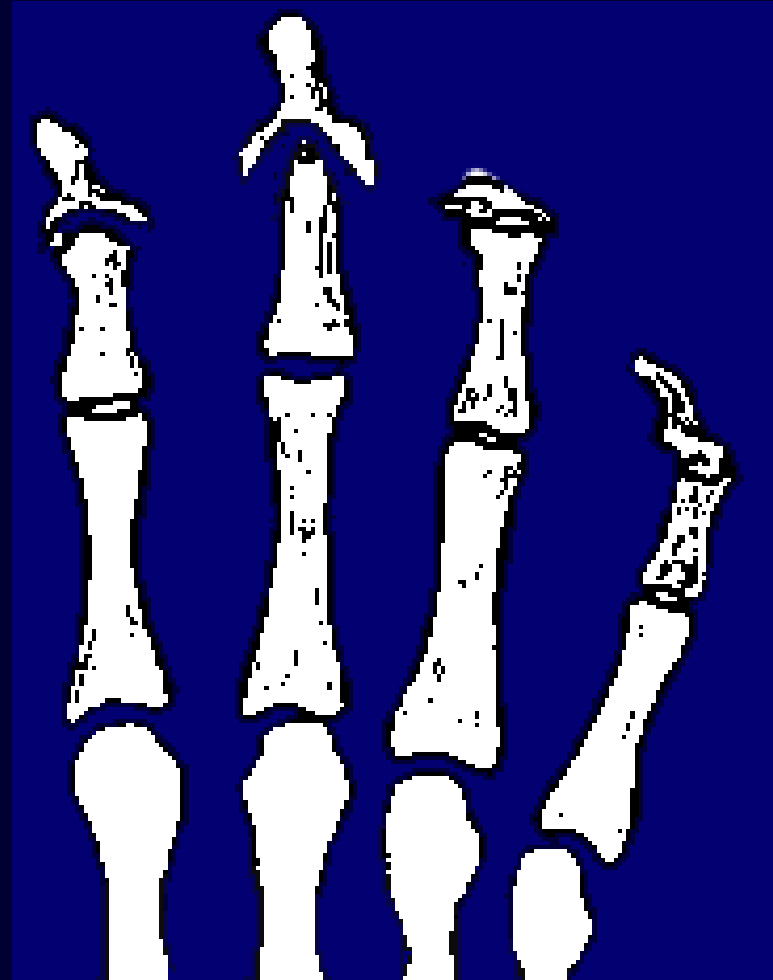
Psoriatic Arthritis

- **Hand**

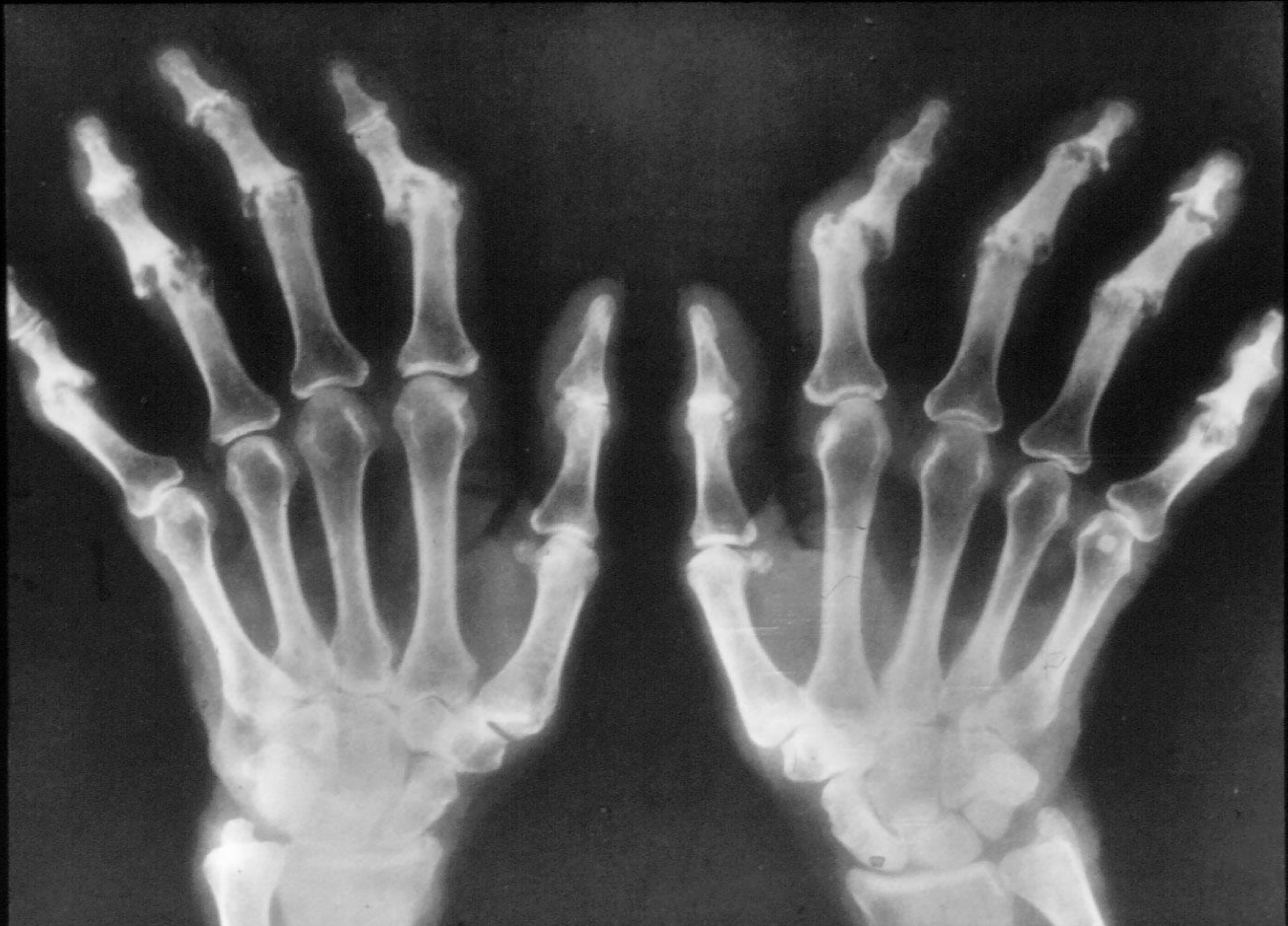- **Distribution is DIPs and PIPs**
- **Rarely single ray pattern**
- **Intra- and inter-articular asymmetry**
- **Erosions of central portion of distal joint surface**
- **Fluffy periosteal response ("mouse ears")**

Psoriatic Arthritis

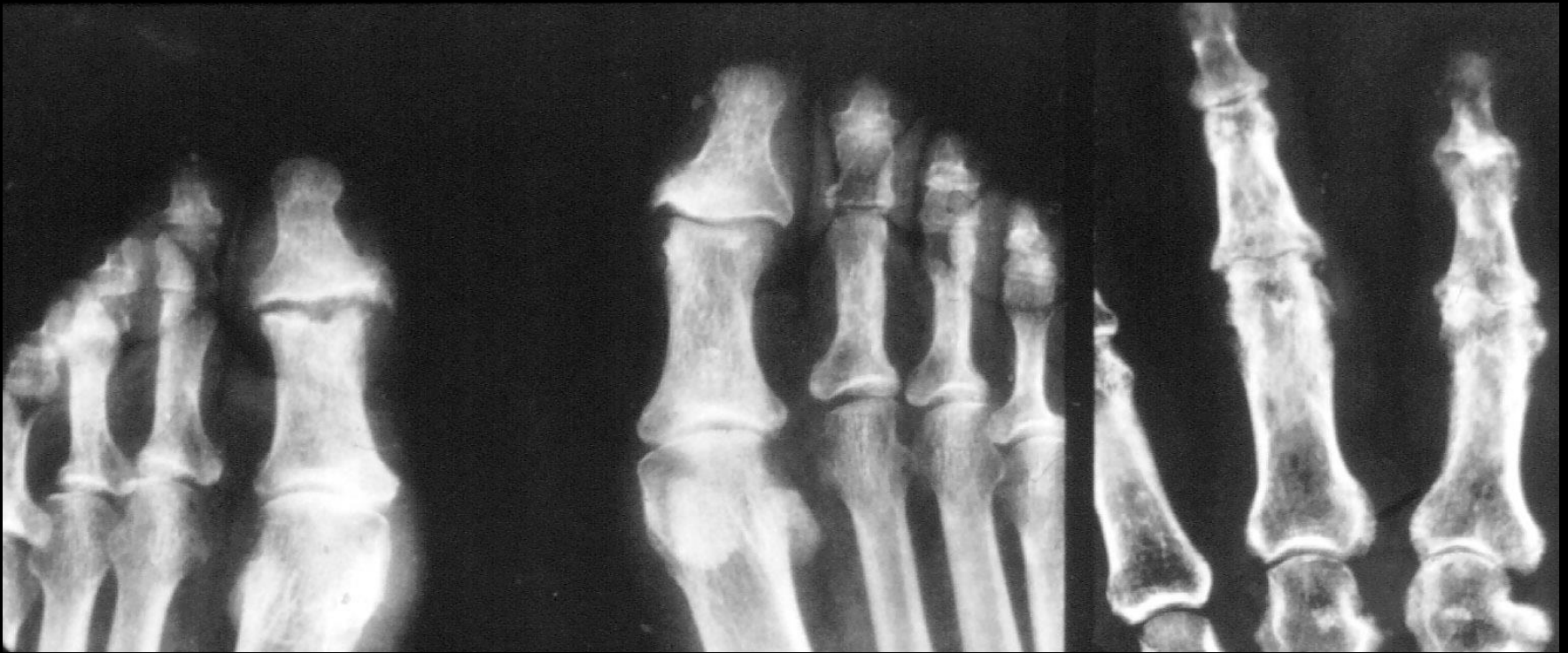- Central erosions on distal articular surface
 - Mouse ears
 - Pencil in cup
 - Balancing pagoda
 - Pestle and mortar
- Eventual destruction
 - Opera glass hand
 - Acro-osteolysis



Psoriatic Arthritis



Psoriatic Arthritis

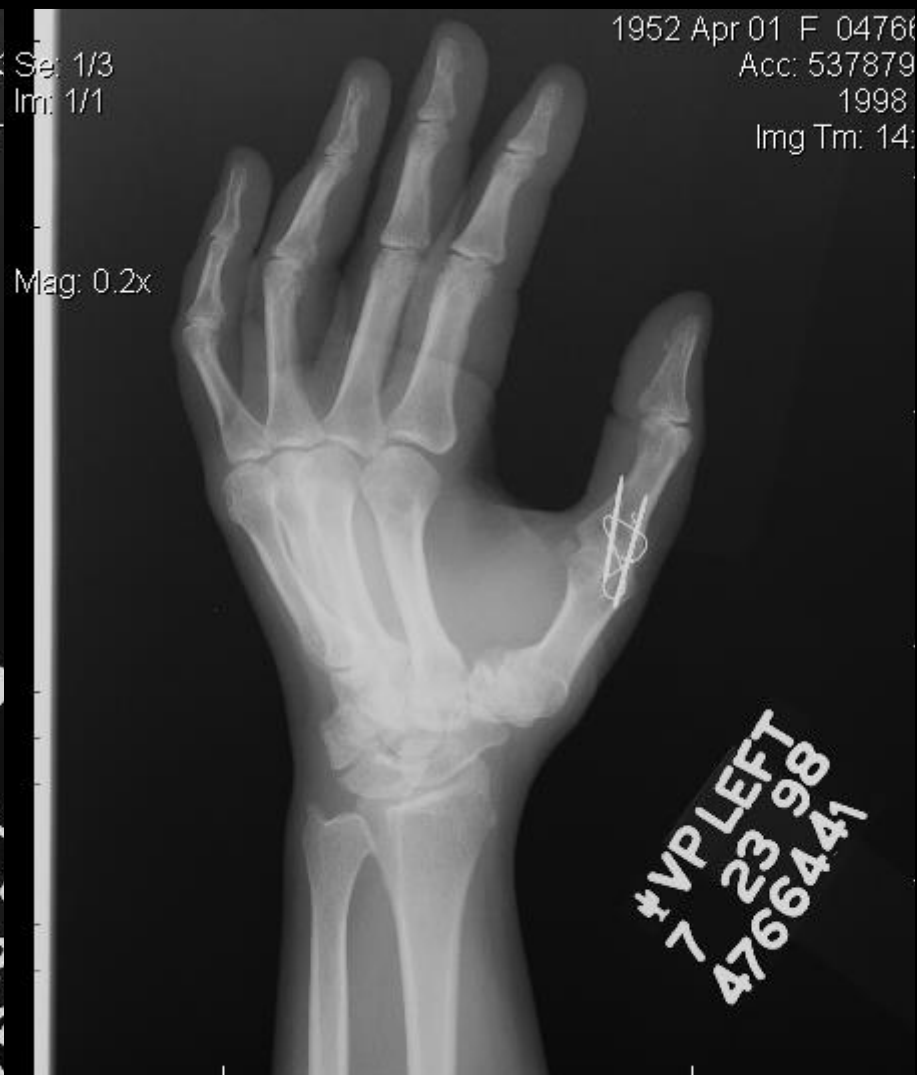
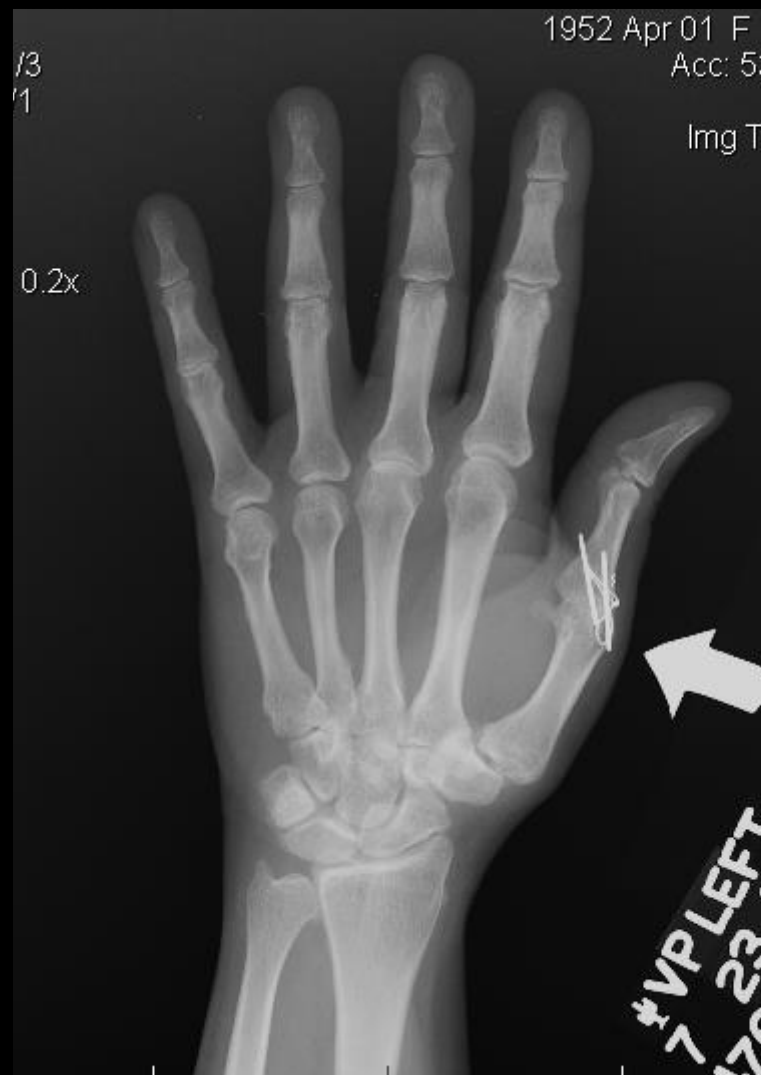
Helen's Drug Therapy

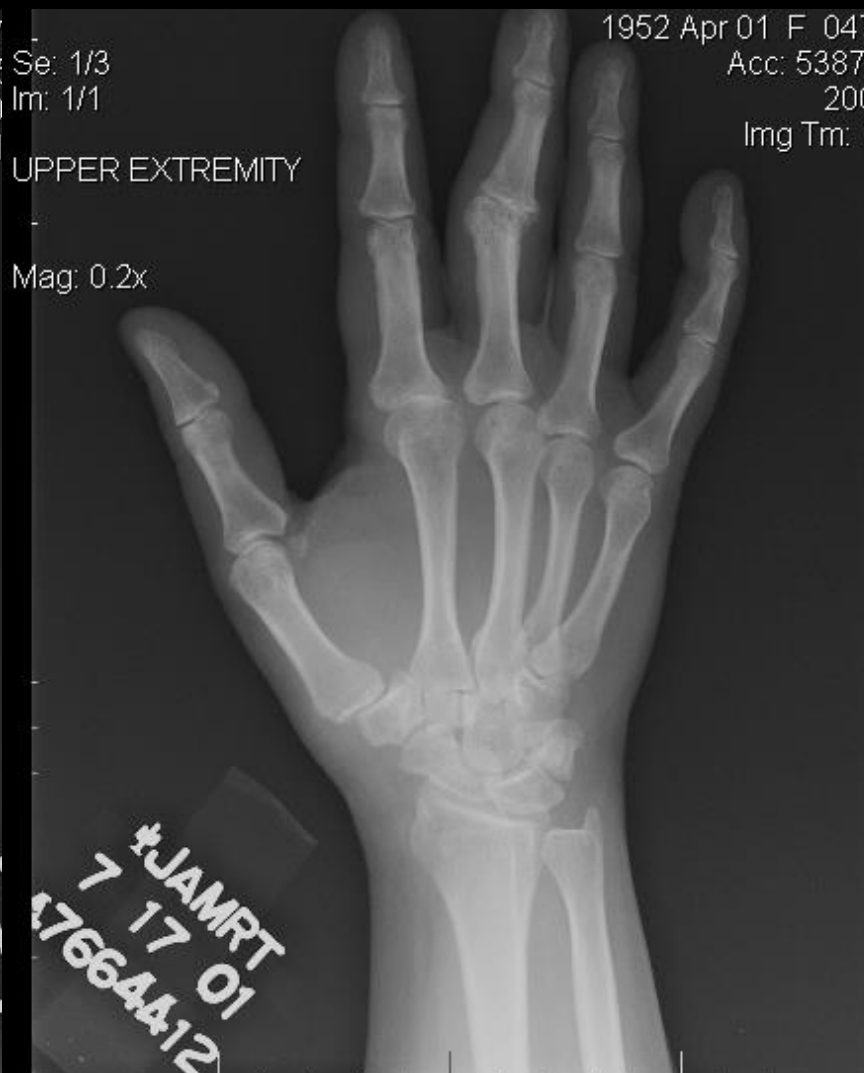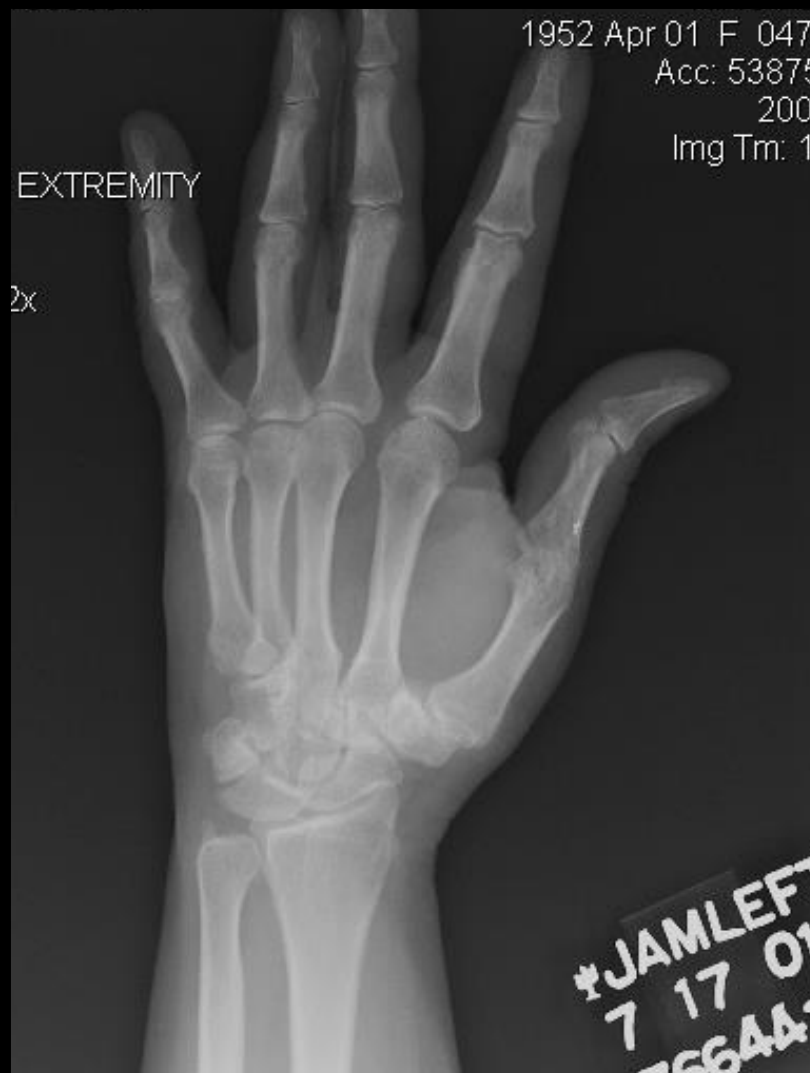- DMARDs = disease modifying anti-rheumatic drugs
- Oral gold, methotrexate, Plaquenil, Arava, Imuran and Enbrel
- All of these failed or had side effects for Helen
 - Side effects included gastric ulcer, heart burn, reflux, voice changes felt to be related to reflux esophagitis
 - Enbrel caused wheezing and shortness of breath
- Steroid injections helped for short periods of time
- Prednisone helped for a long time

Helen's Surgeries

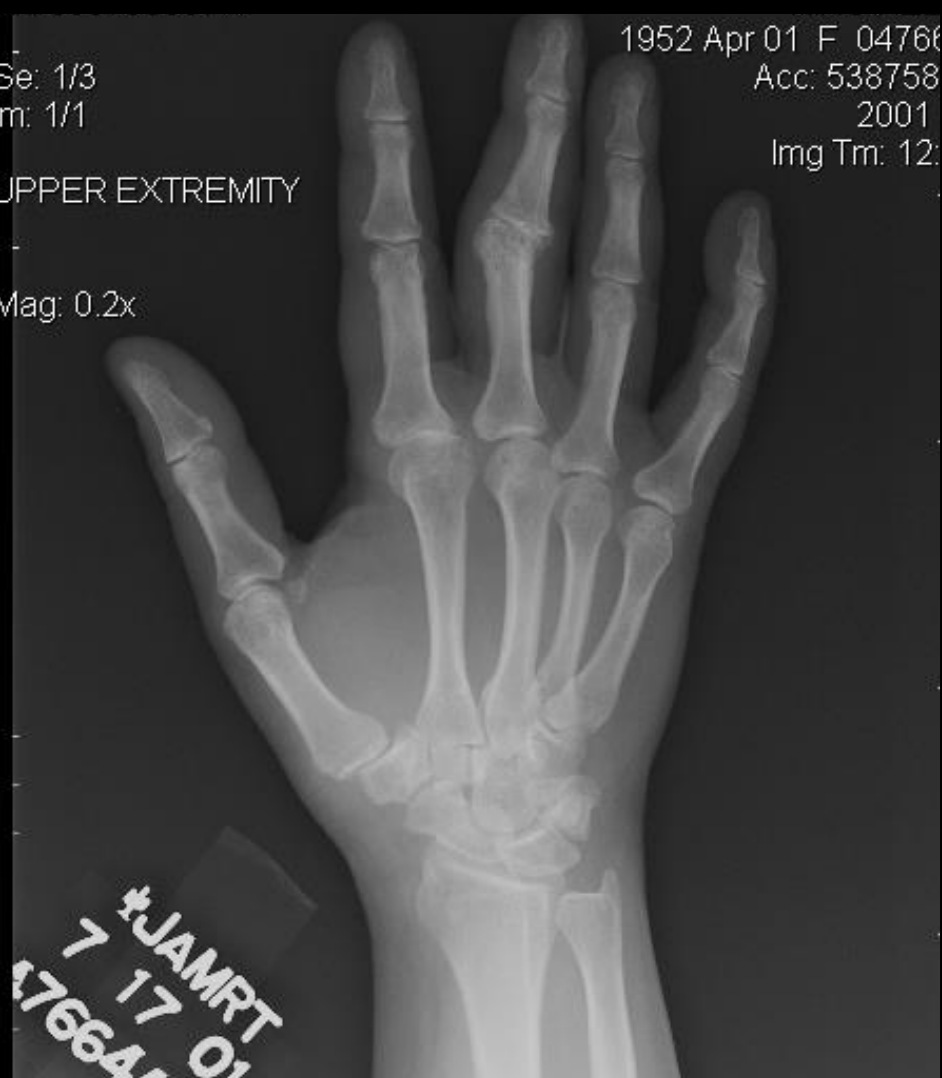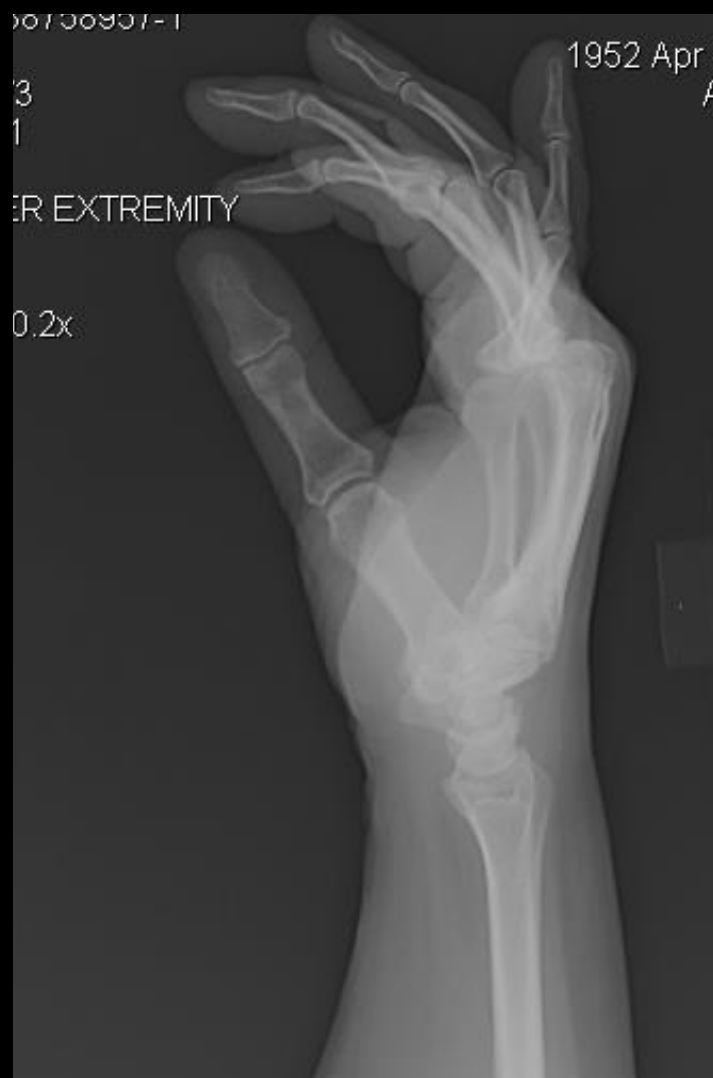- **Synovectomies and tendon repair of multiple joints**
- **Silastic implant arthroplasty MCP joint right index finger**
- **Arthrodeses MCP joints of thumbs**
- **Joint realignment right middle finger**
- **Right trapeziectomy with abductor pollicis longus suspension plasty**



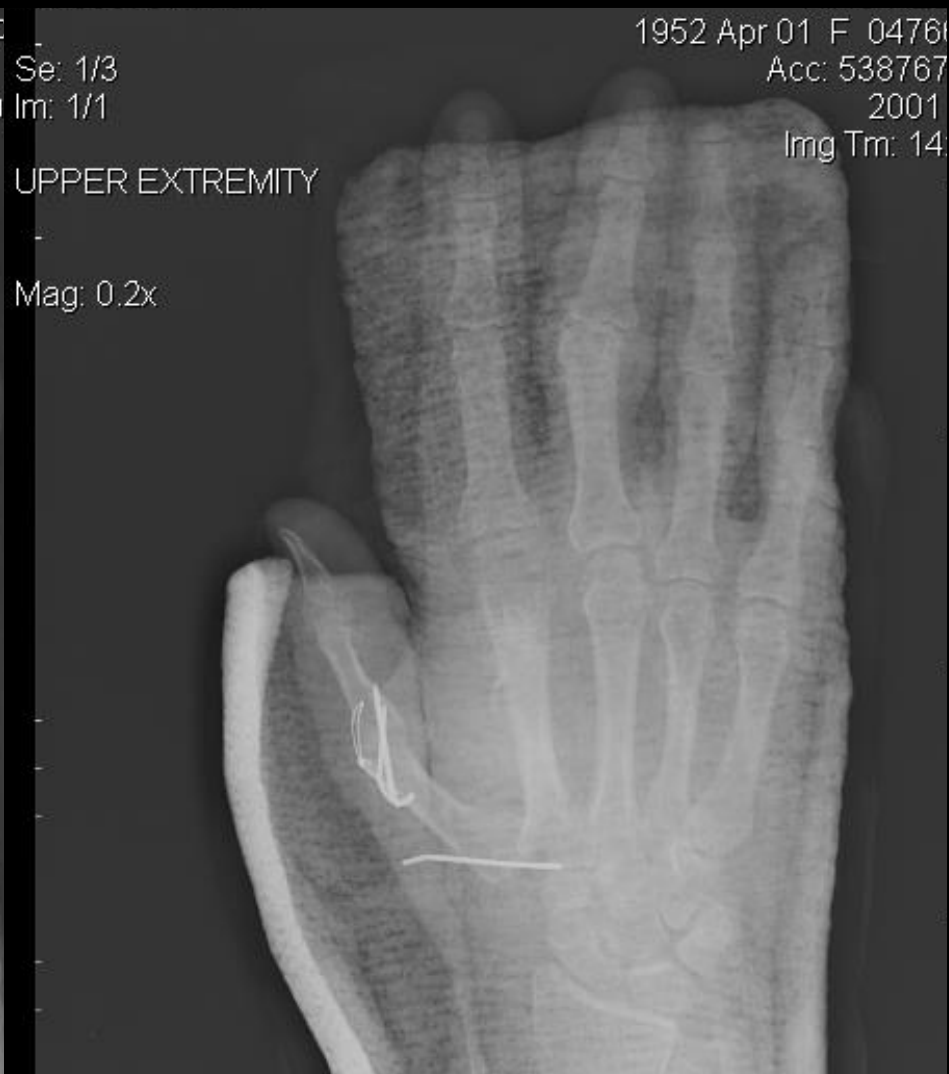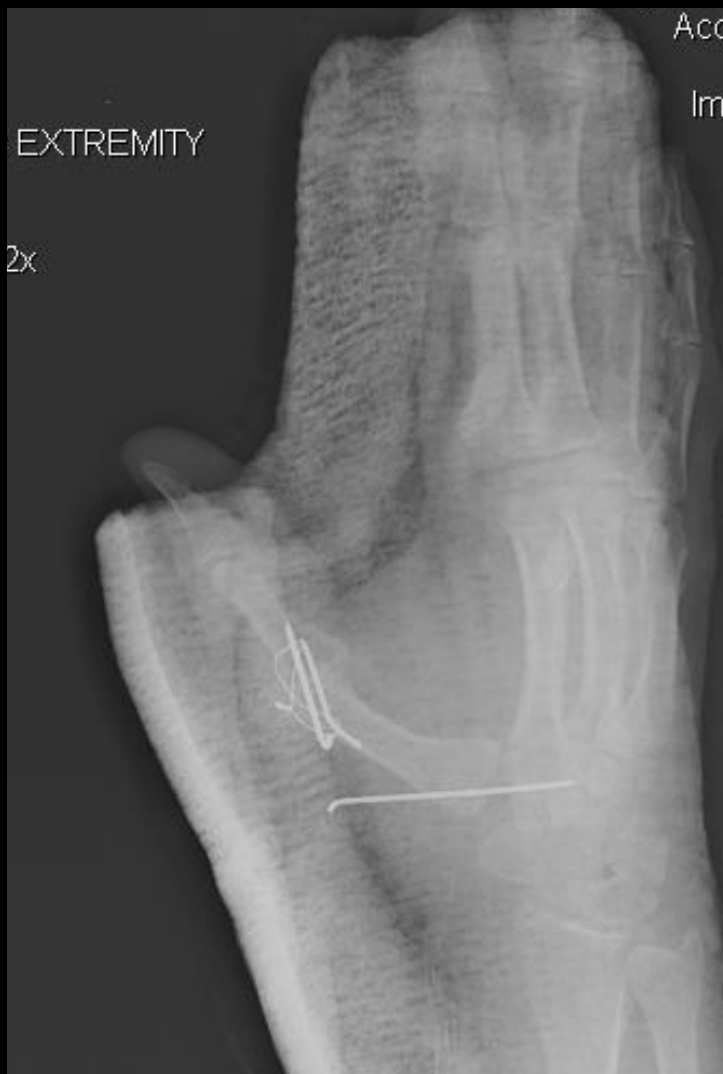7-23-1998



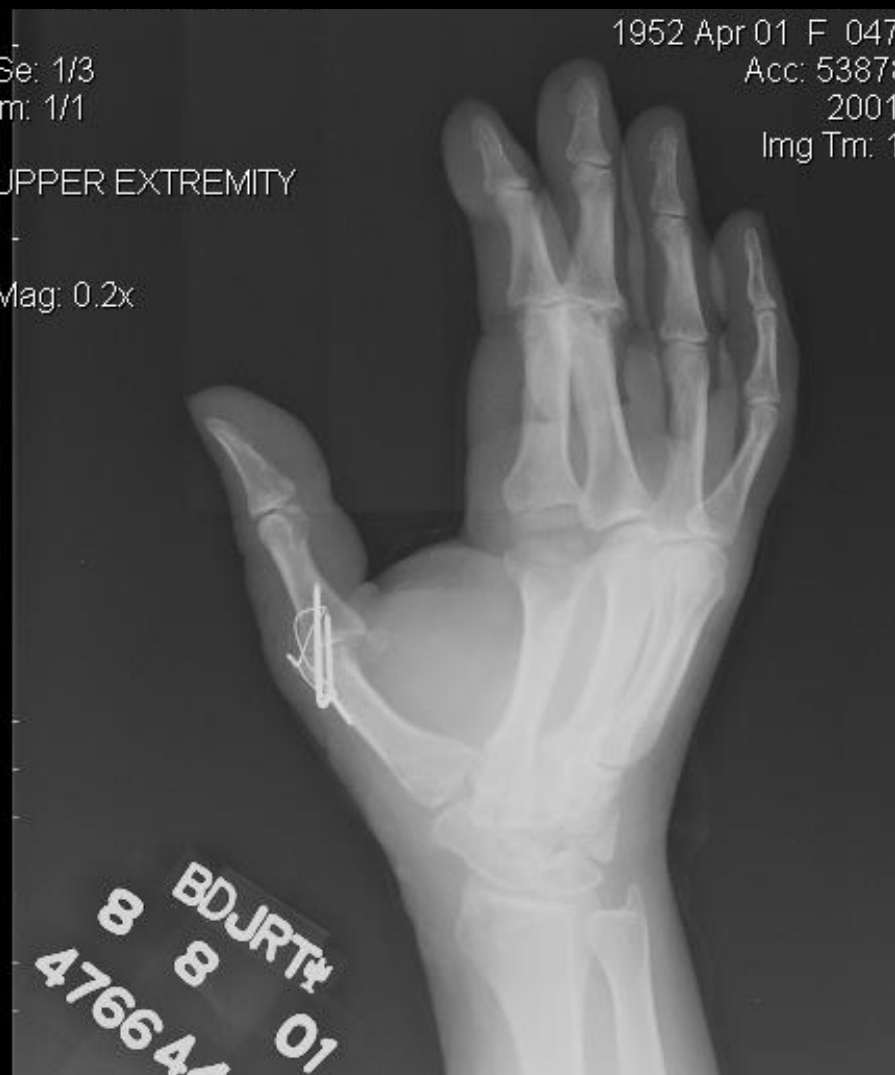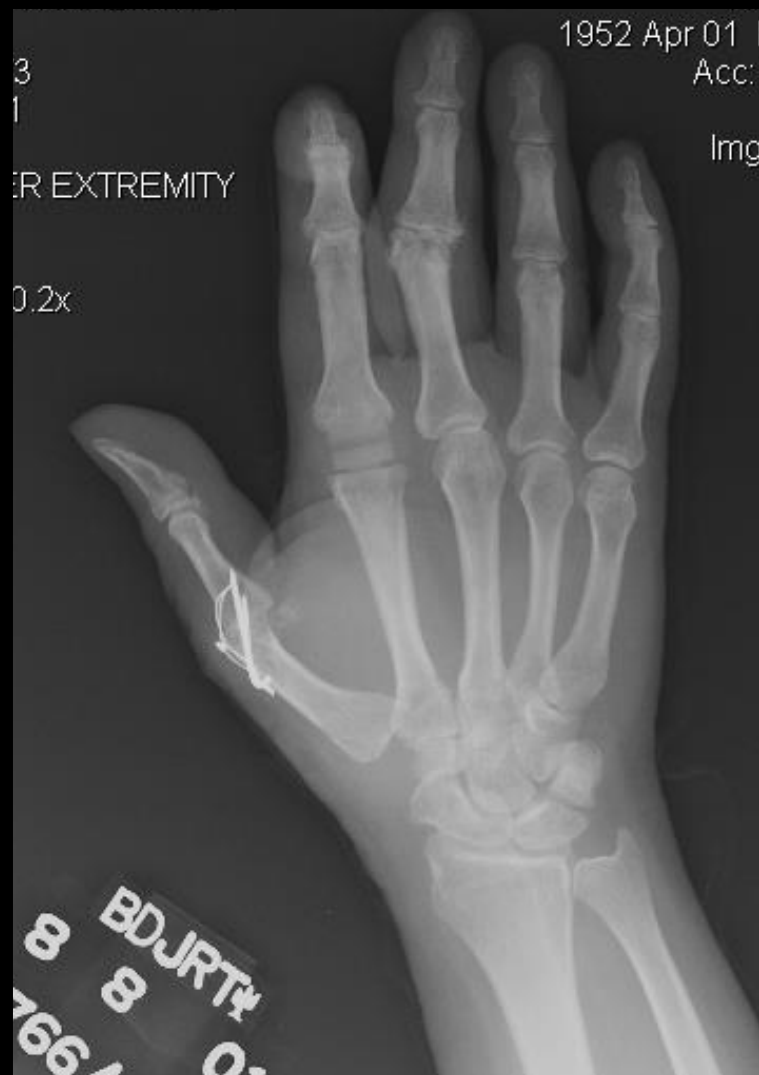7-17-2001



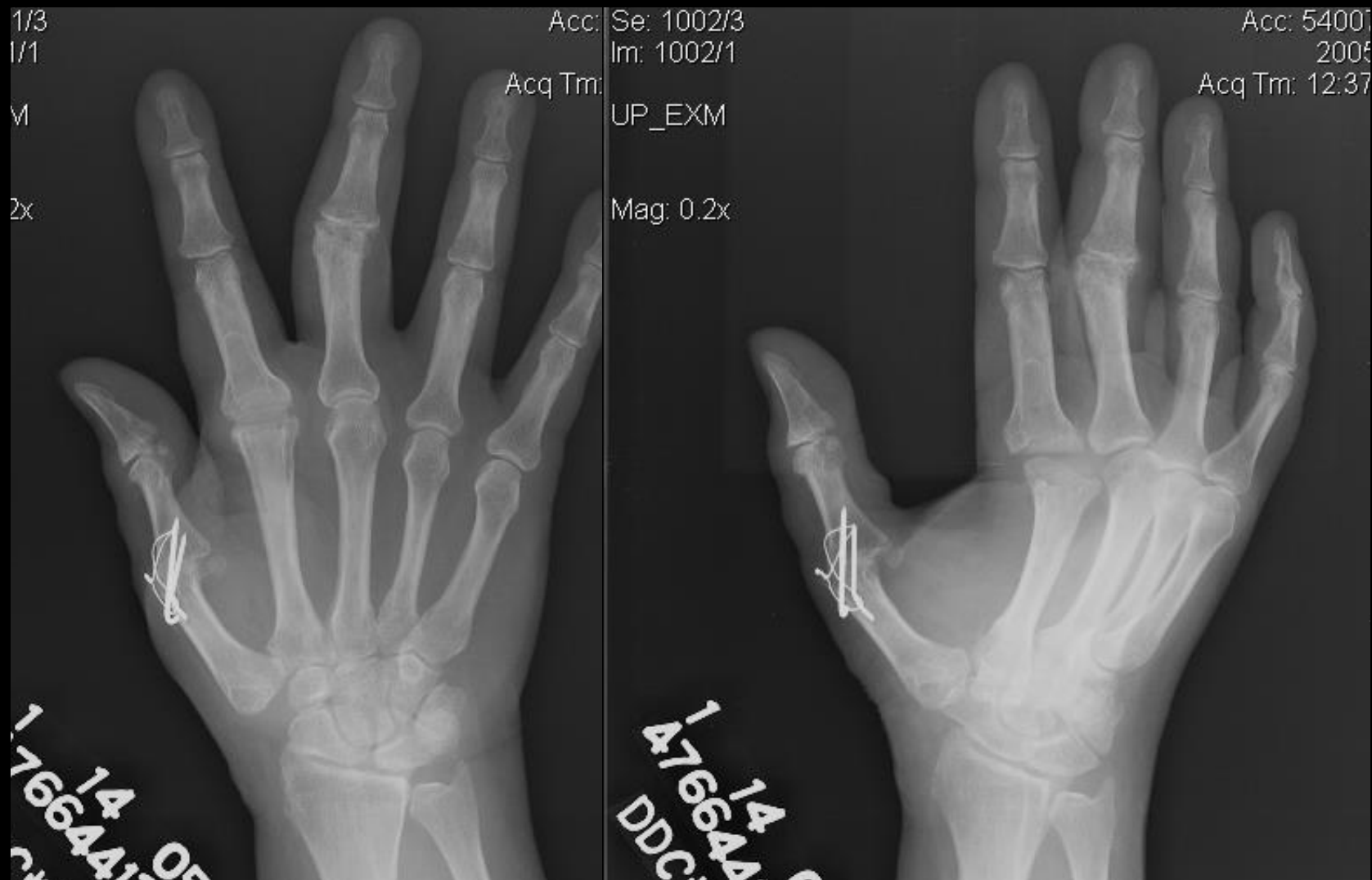7-17-2001

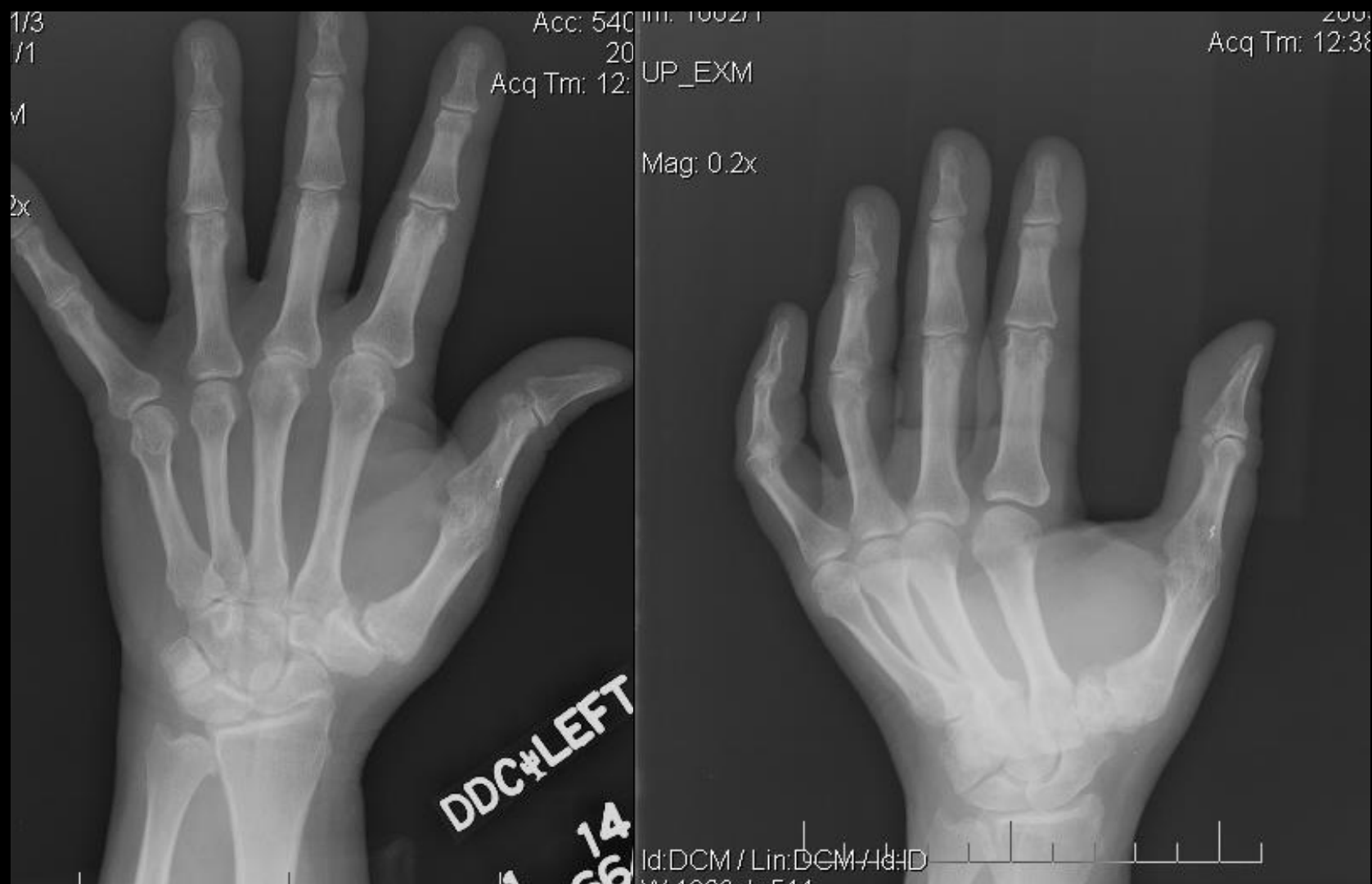

7-20-2001



8-8-2001





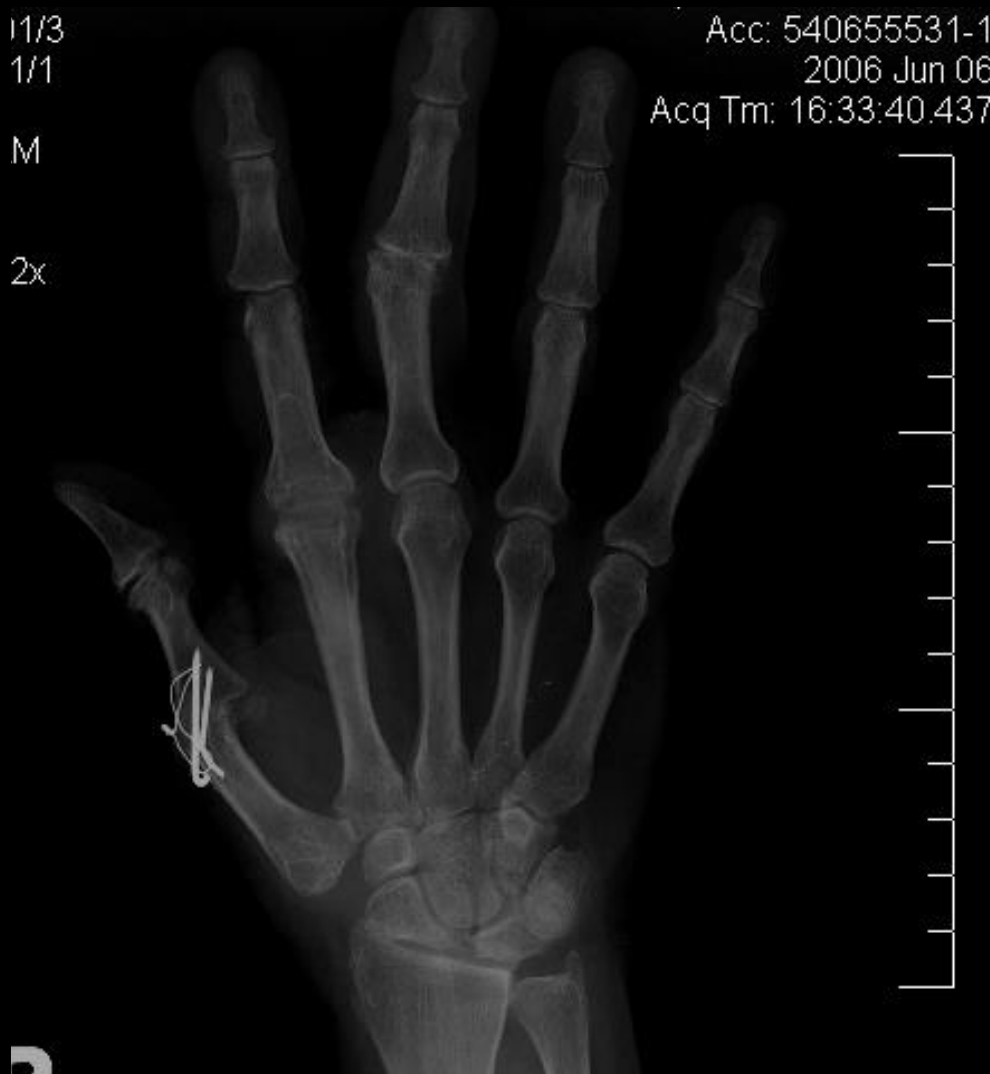1-14-2005

11/3
1/1

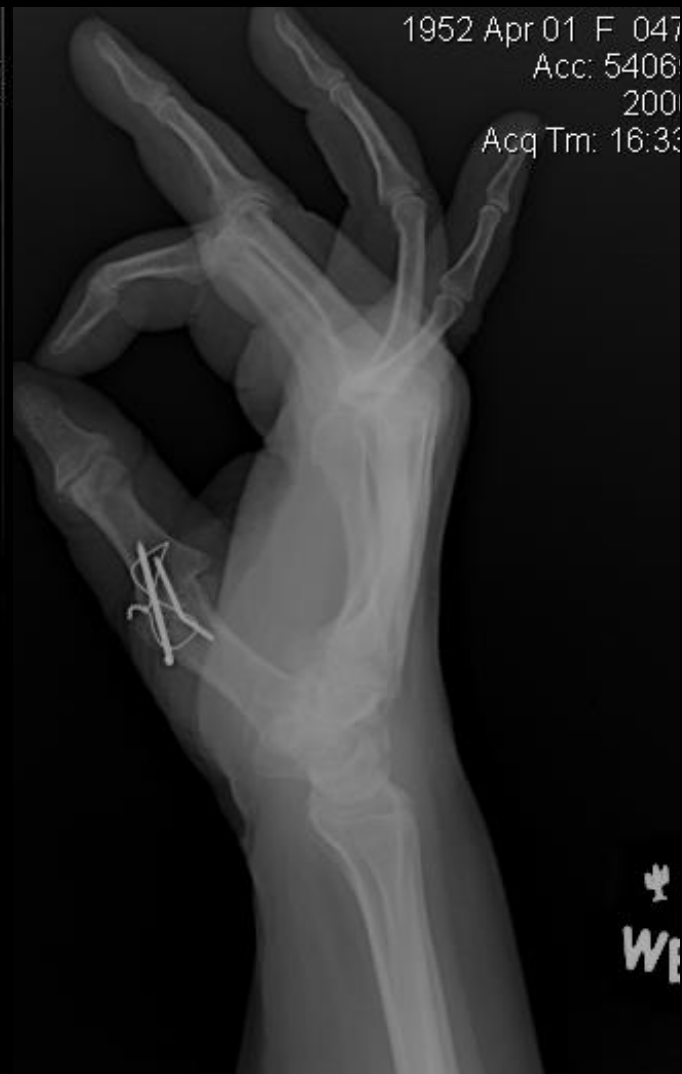M

2x

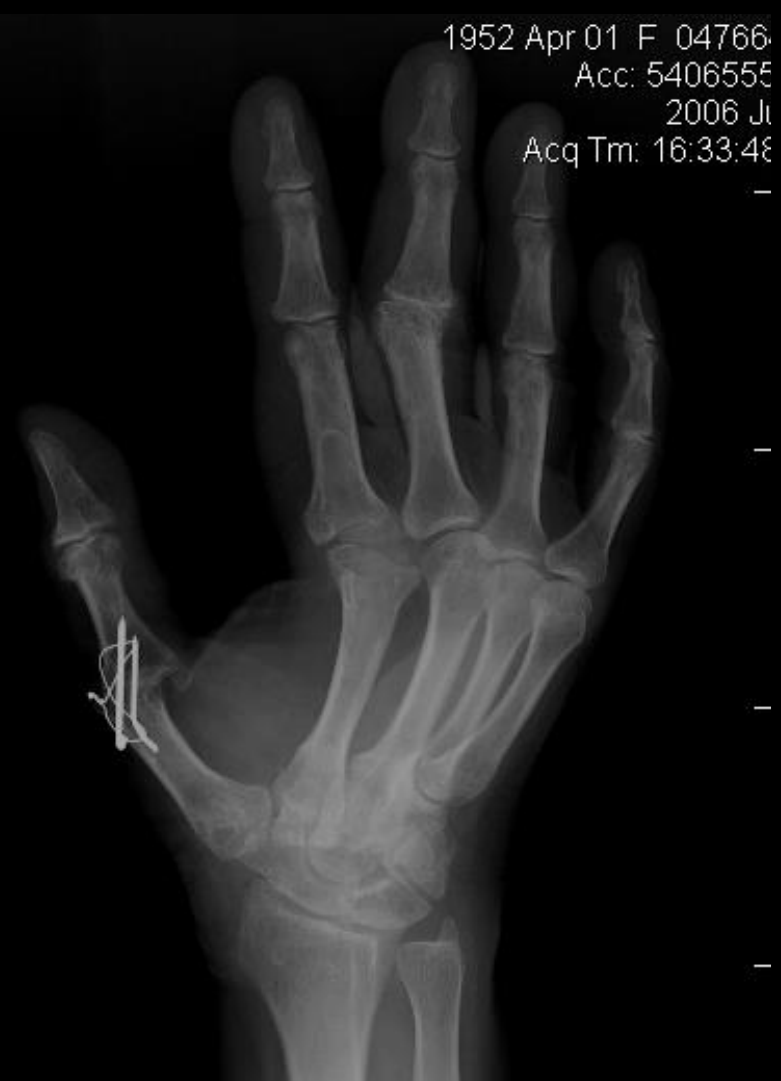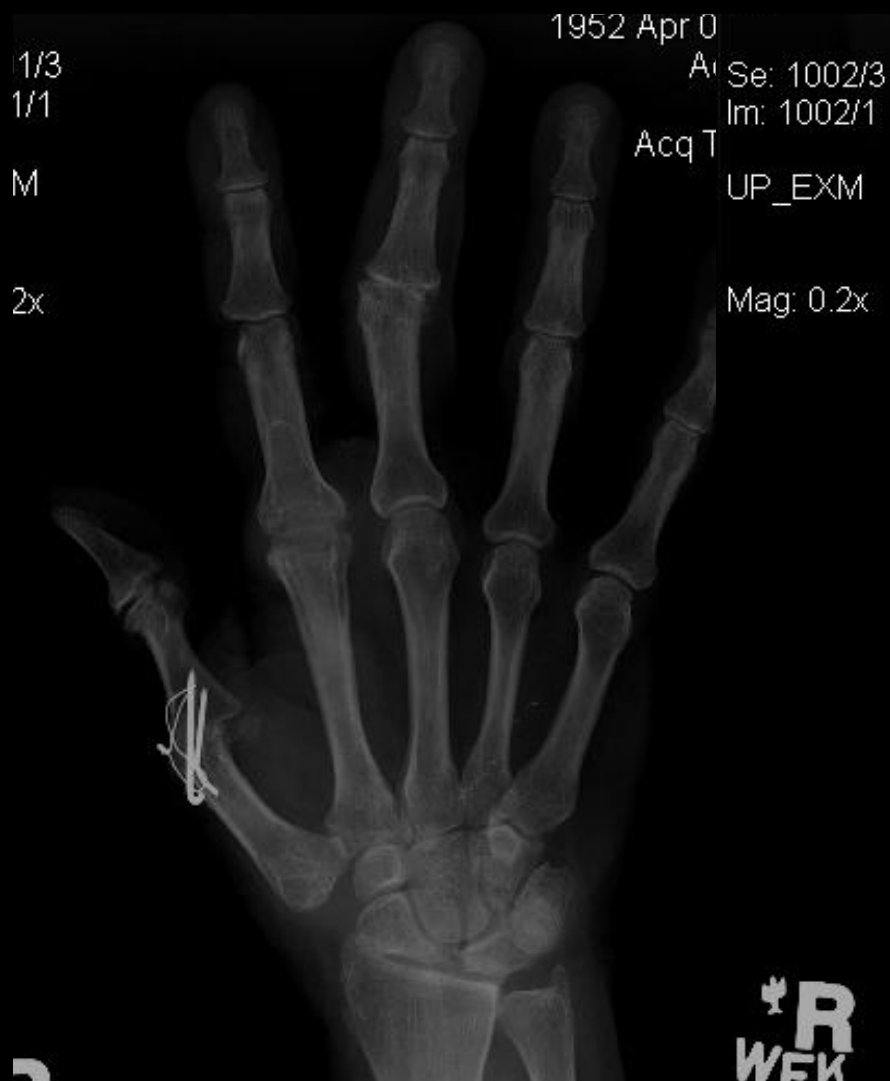Acc: 540655531-1
2006 Jun 06
Acq Tm: 16:33:40.437



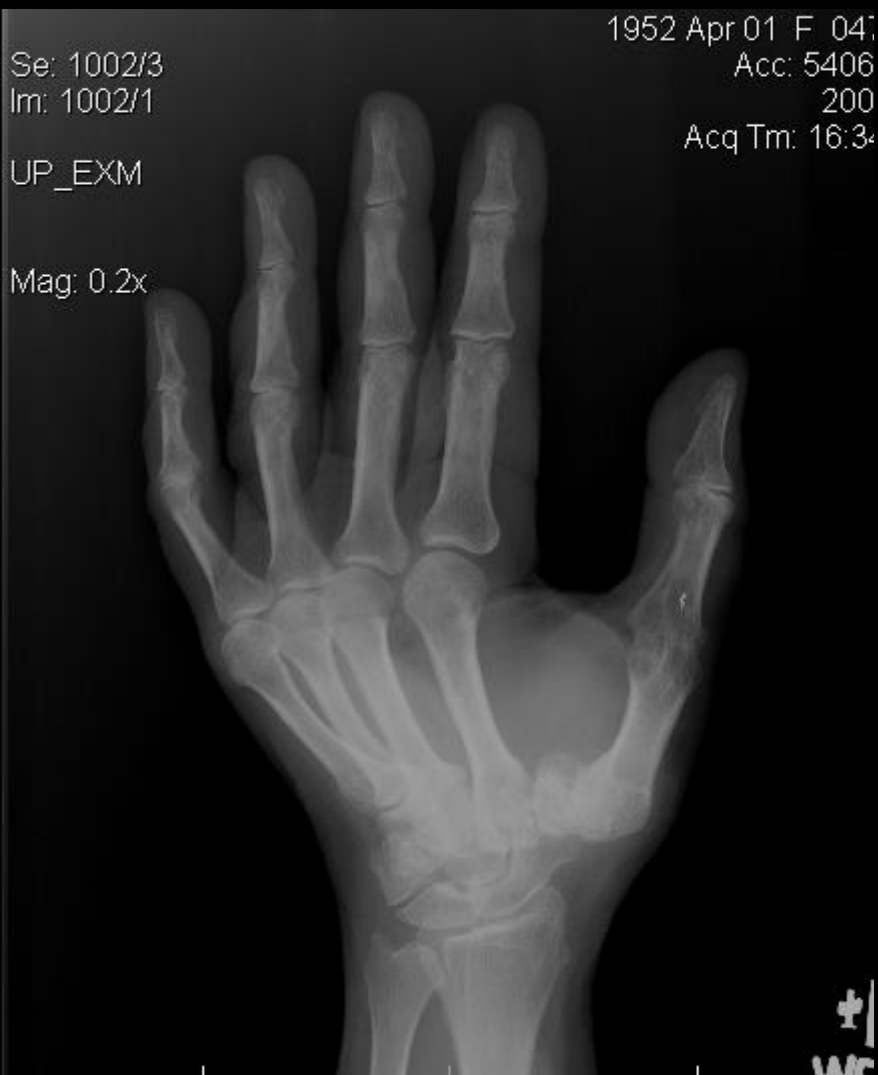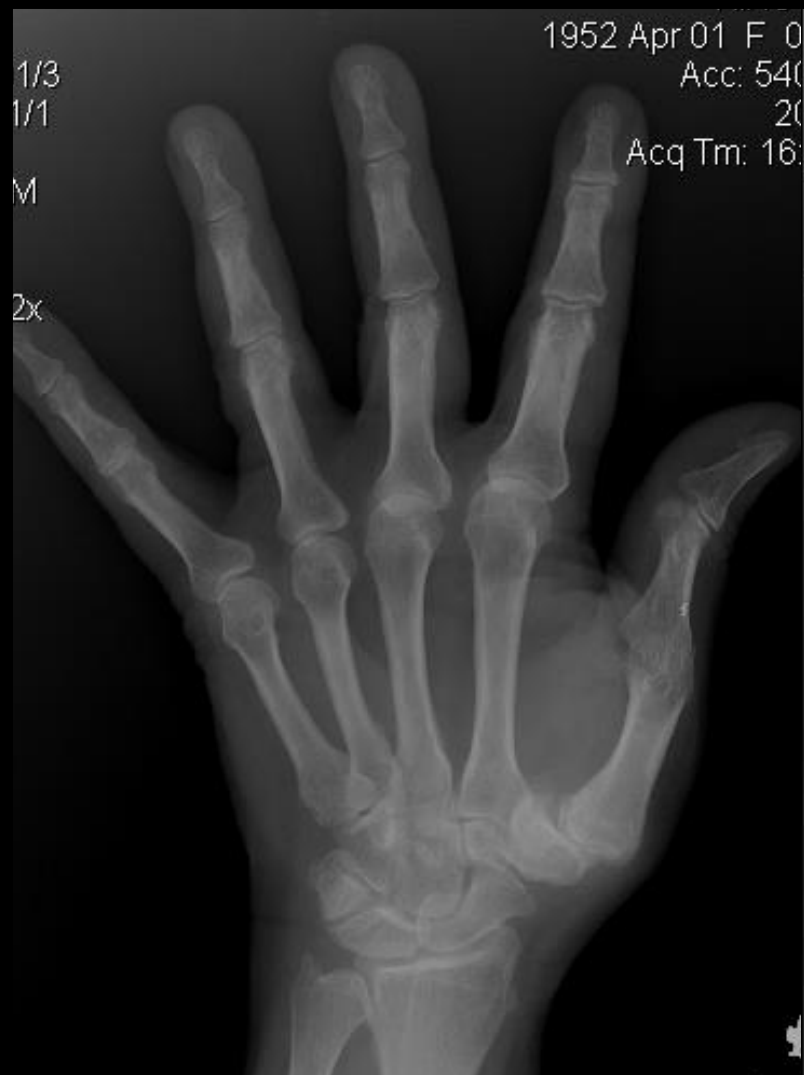1952 Apr 01 F 047
Acc: 5406
200
Acq Tm: 16:33



6-6-2006



6-6-2006



6-6-2006





**Drs. Joseph Howe, Vinton "Vin" Albers, Terry Yochum, Don Tompkins,
Andrew "Andy" Jackson, Raymond "Ray" Conley and Michael "Mike" Buehler**



Drs. John Taylor, Reed Phillips, Sheri Jaeger, Joseph Howe and Terry Yochum



Dr. Joseph Howe with his Los Angeles College of Chiropractic (LACC) radiology residents

External Aids

- Splints
- Braces
- Orthotics, proper shoes
- Paraffin bath
- Soaking in warm water

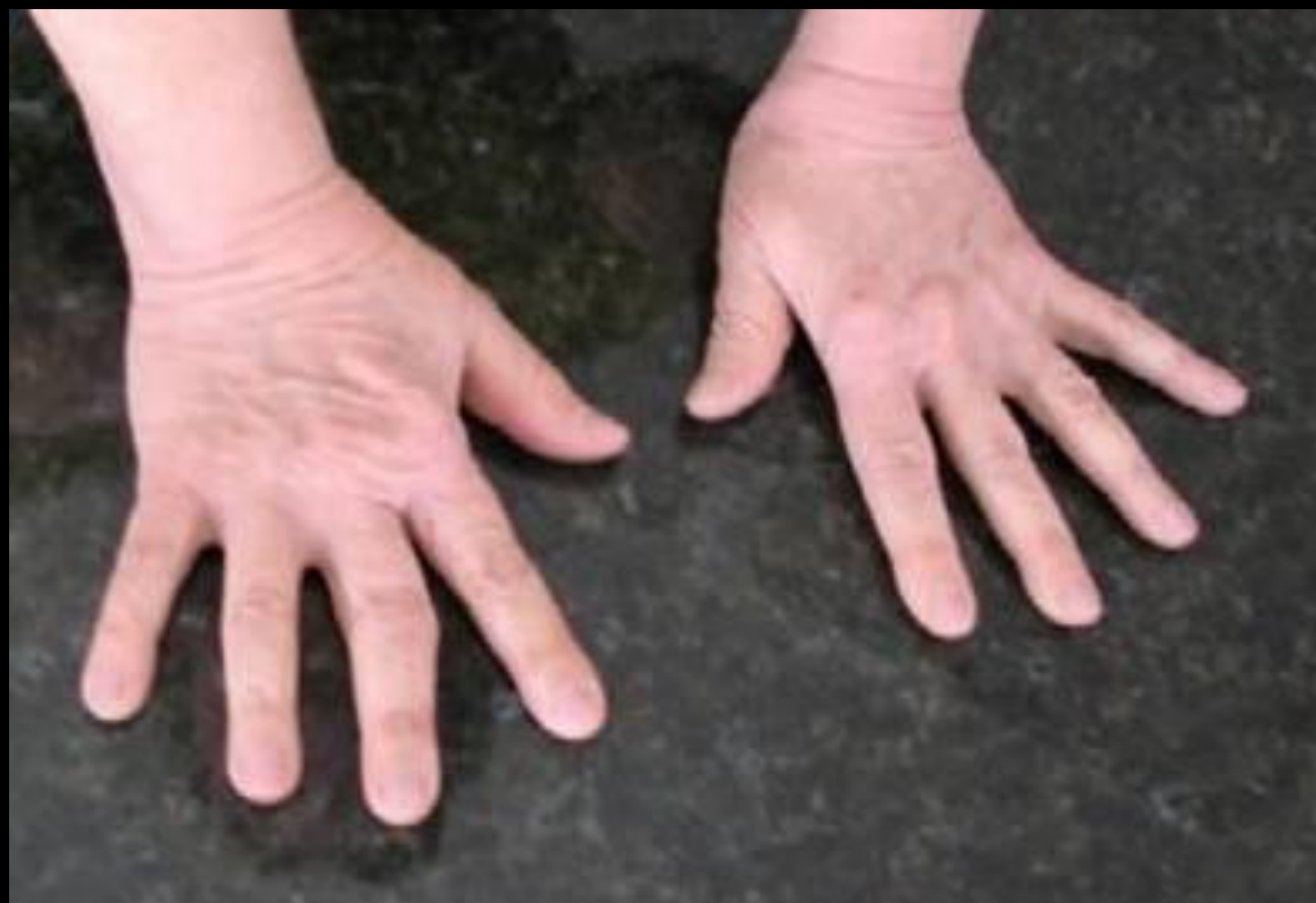


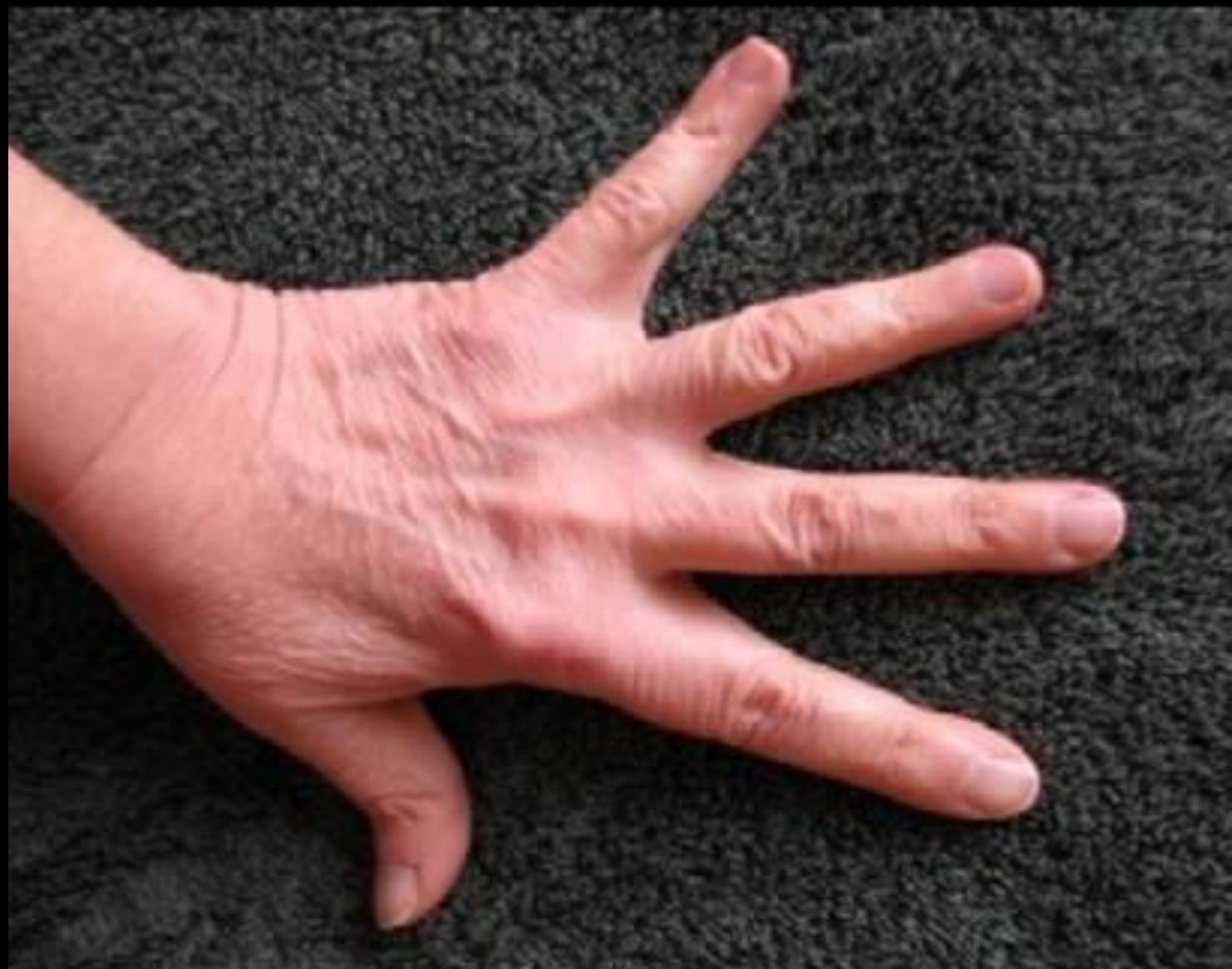


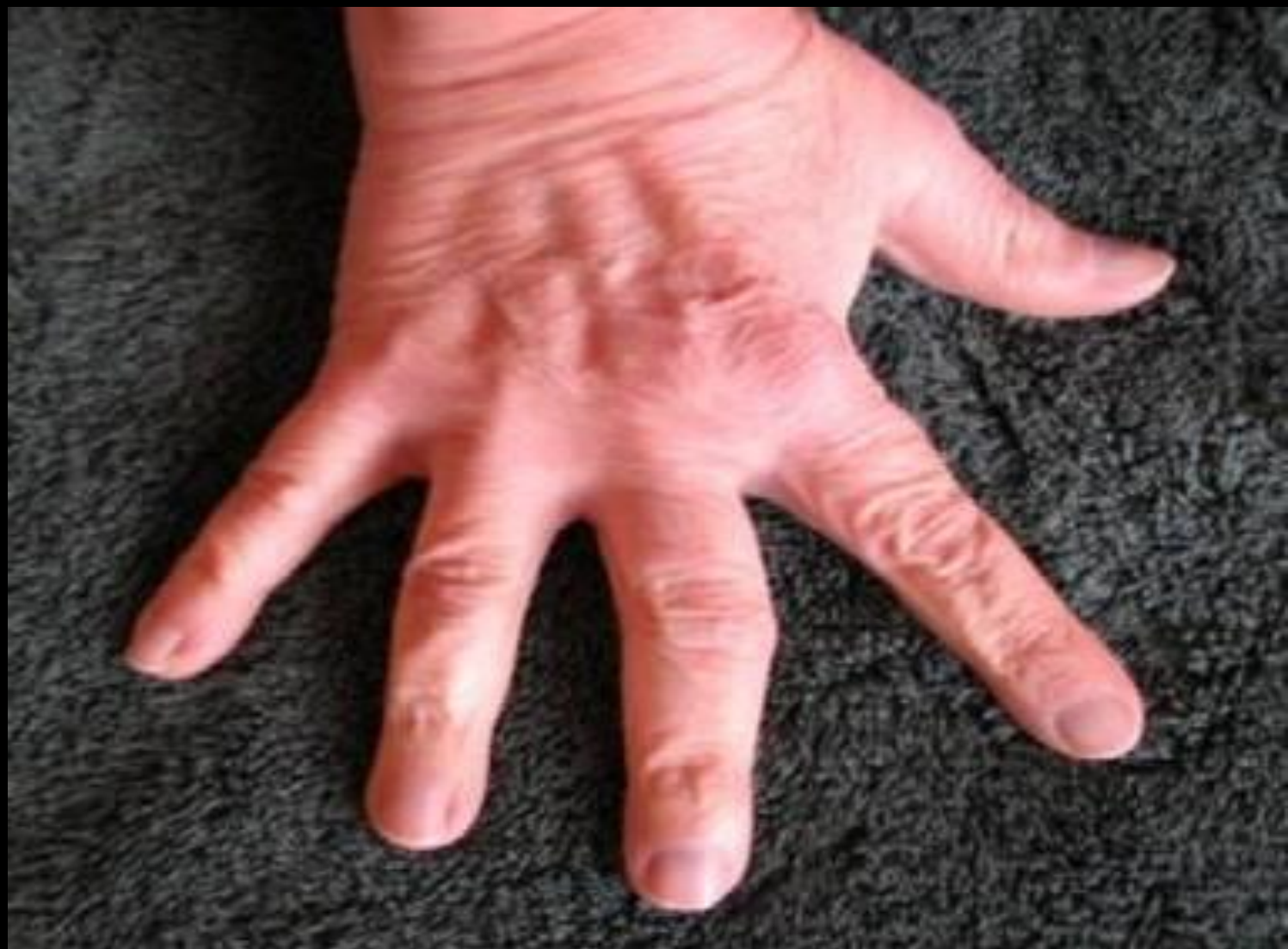






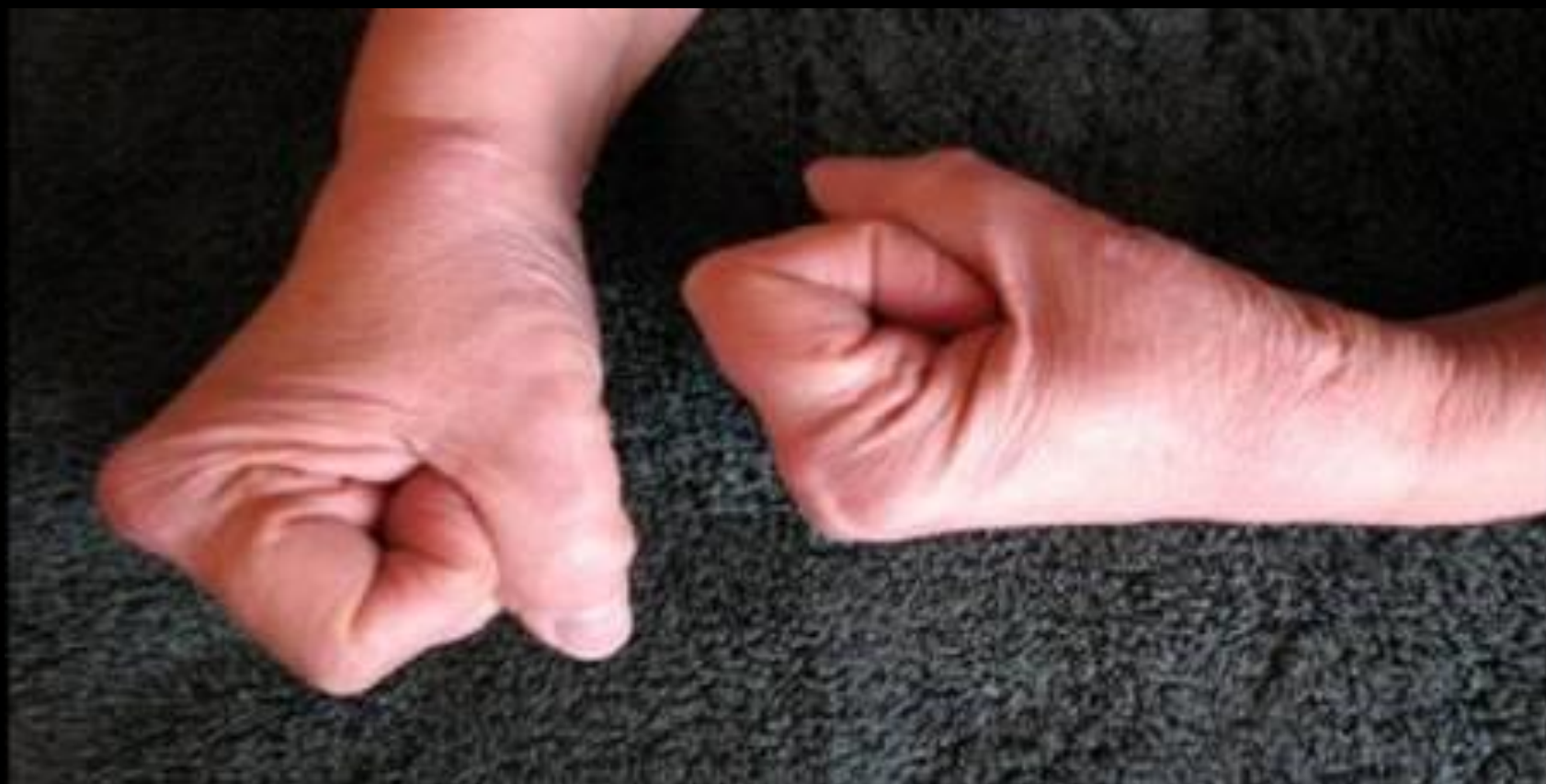






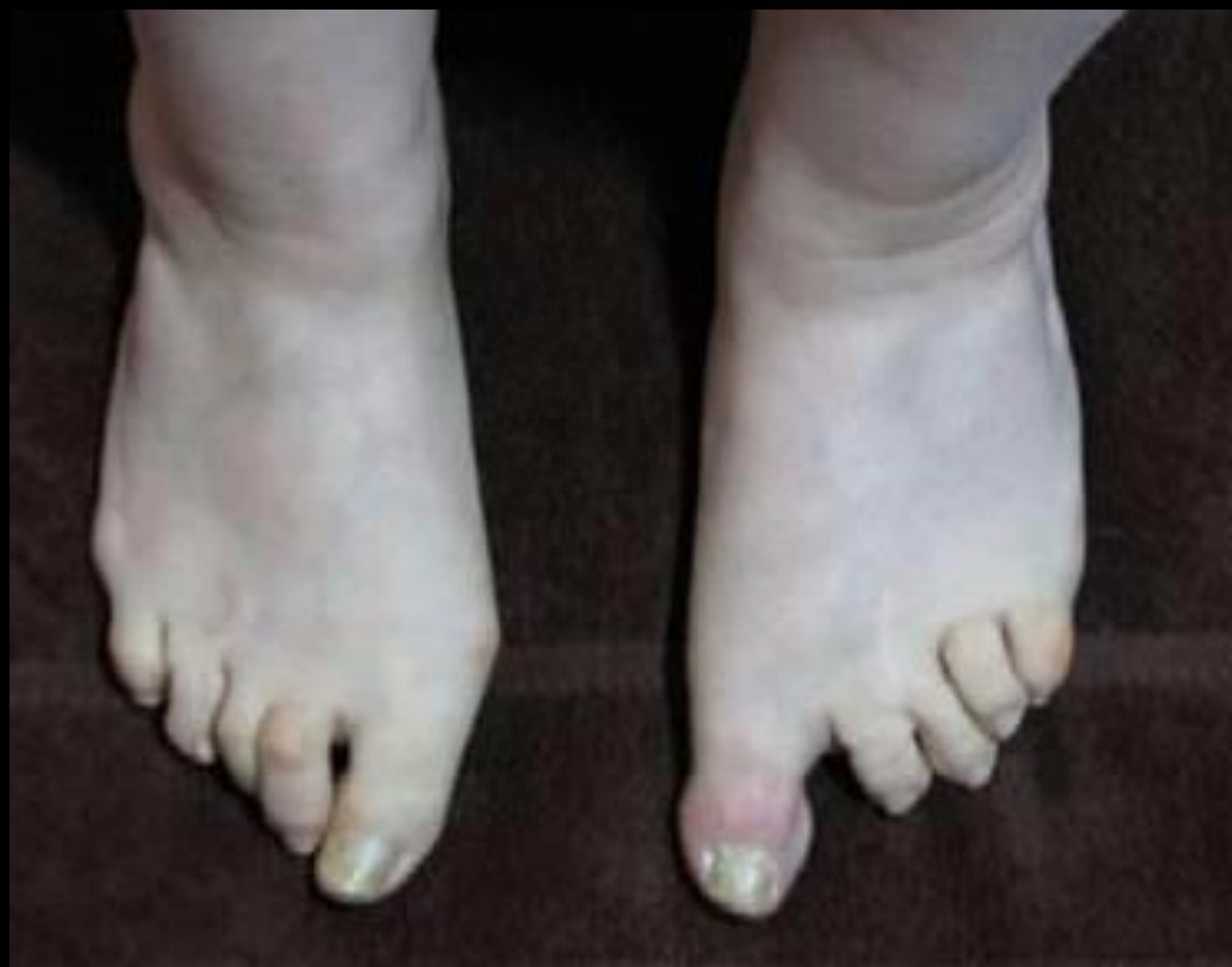

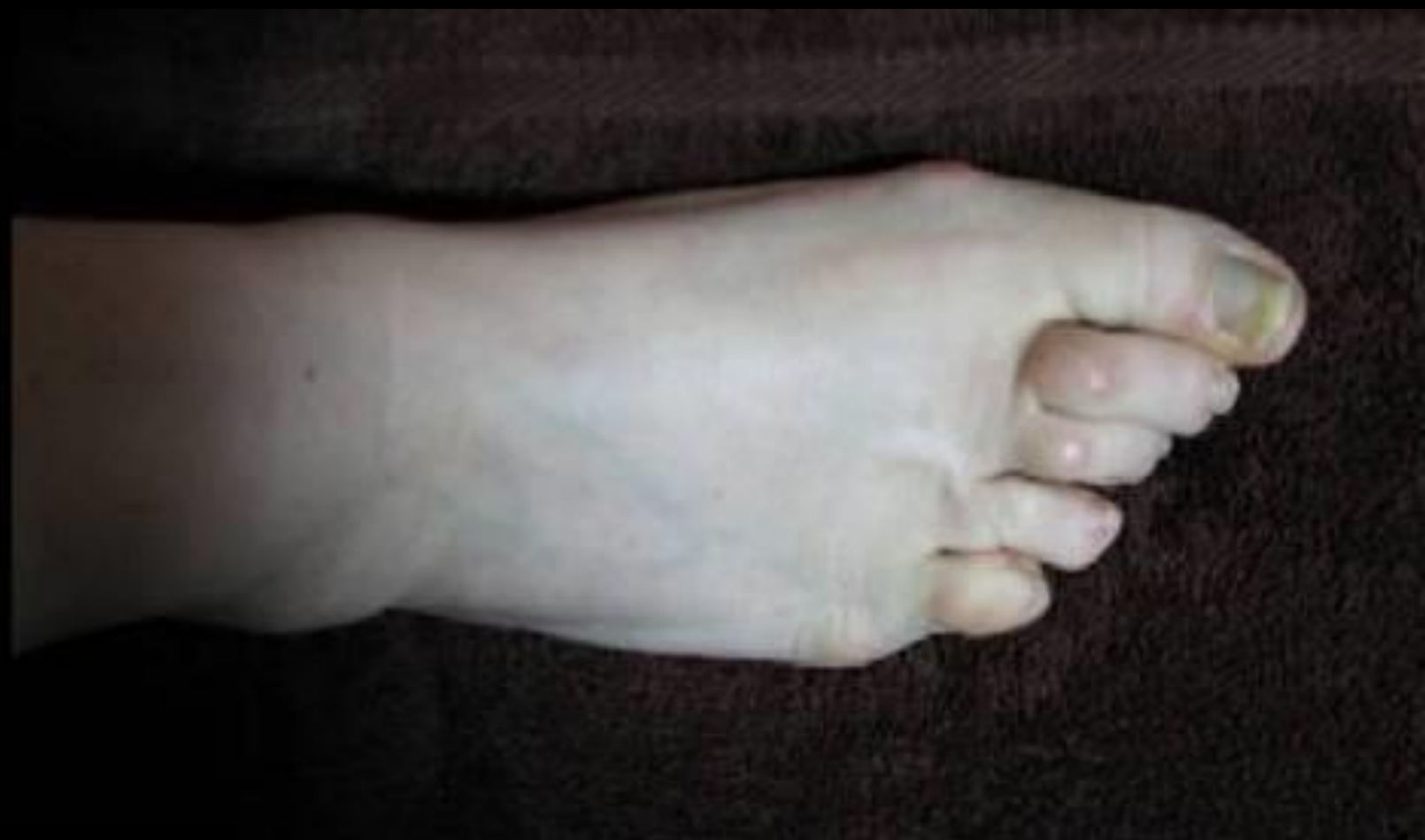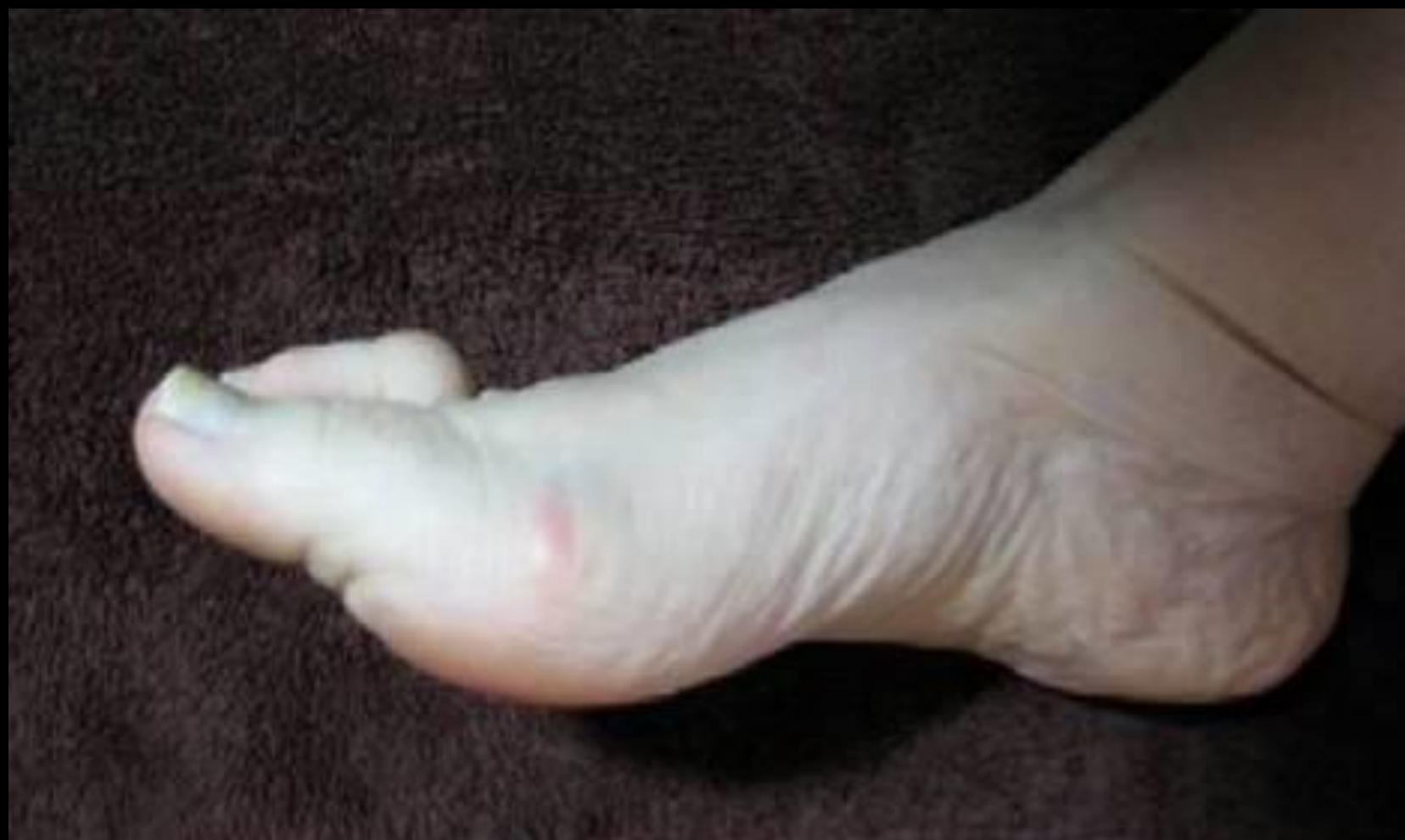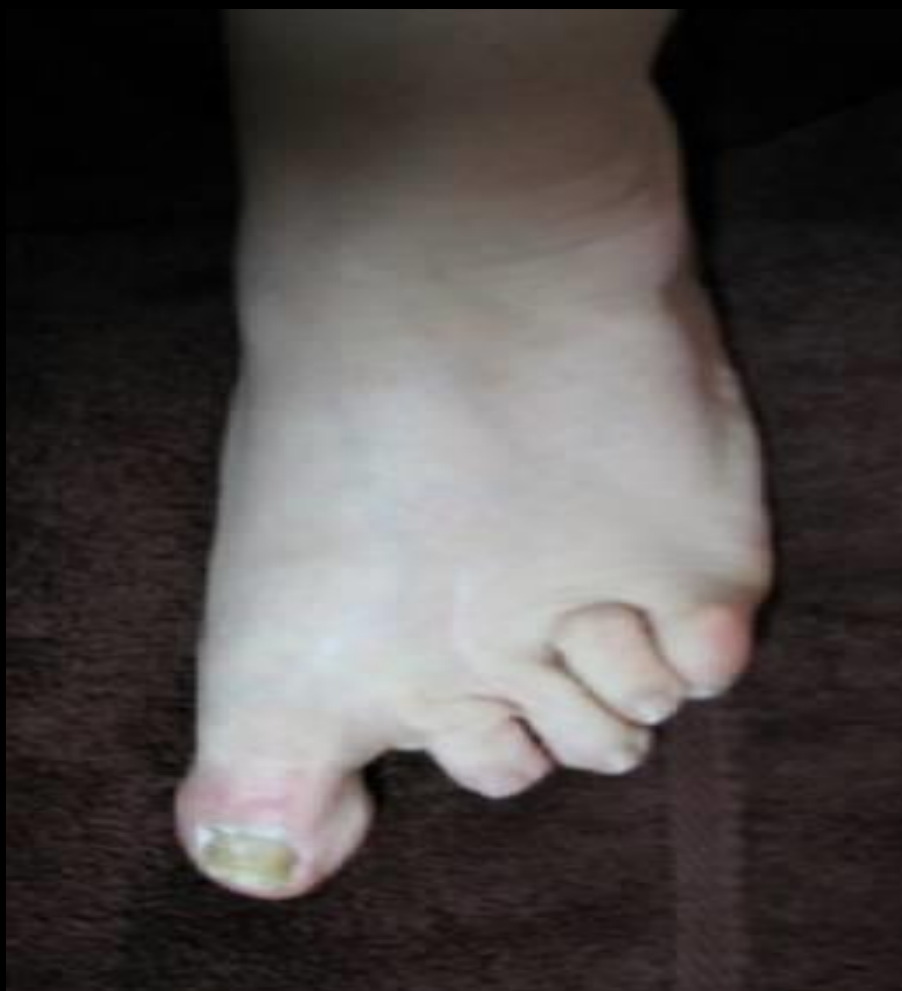Helen's Feet

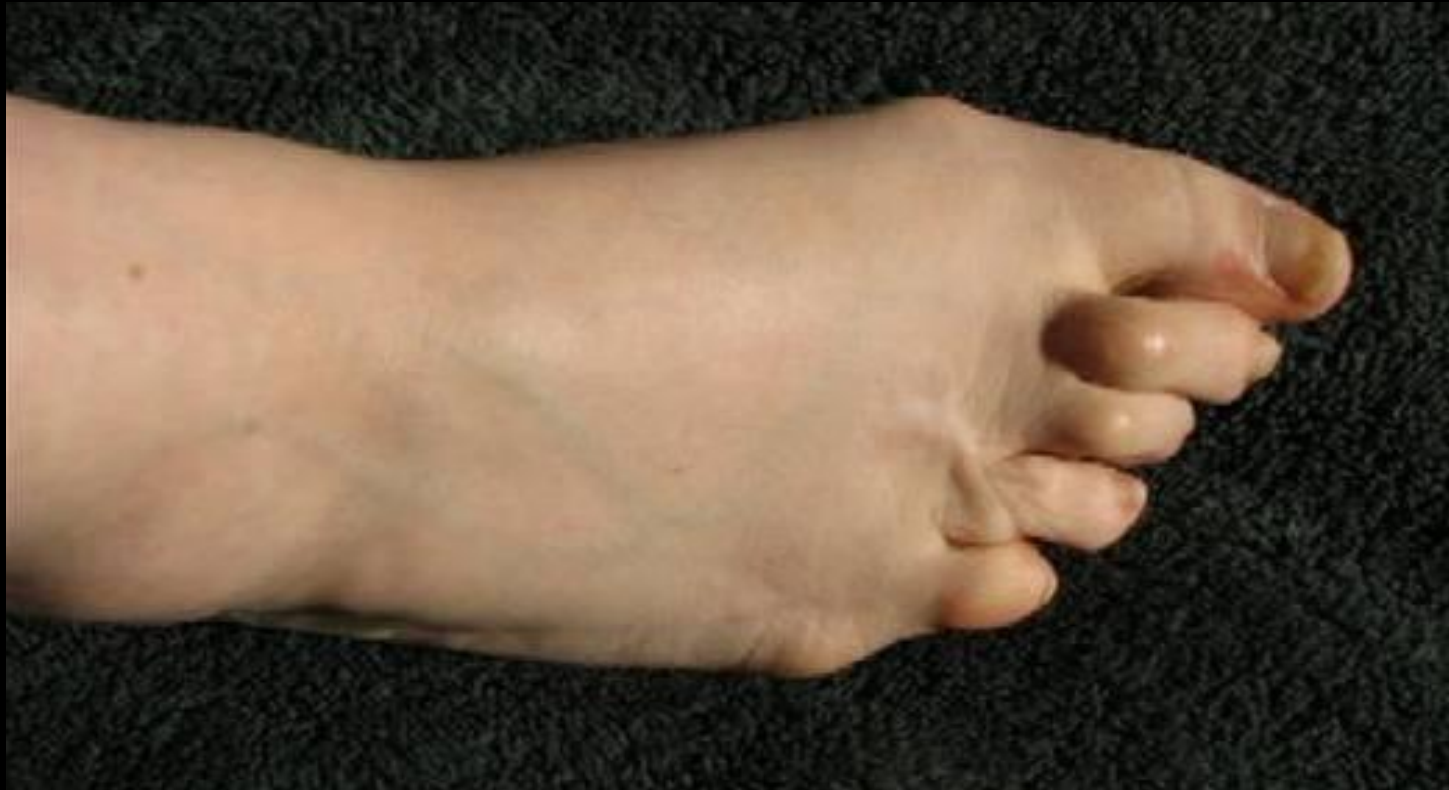- **Helen has had numerous surgeries on her feet**
- **Not as successful as her hands**
- **She walks 2 miles in 30 minutes weather permitting**
- **Rides a bike if she can't walk**

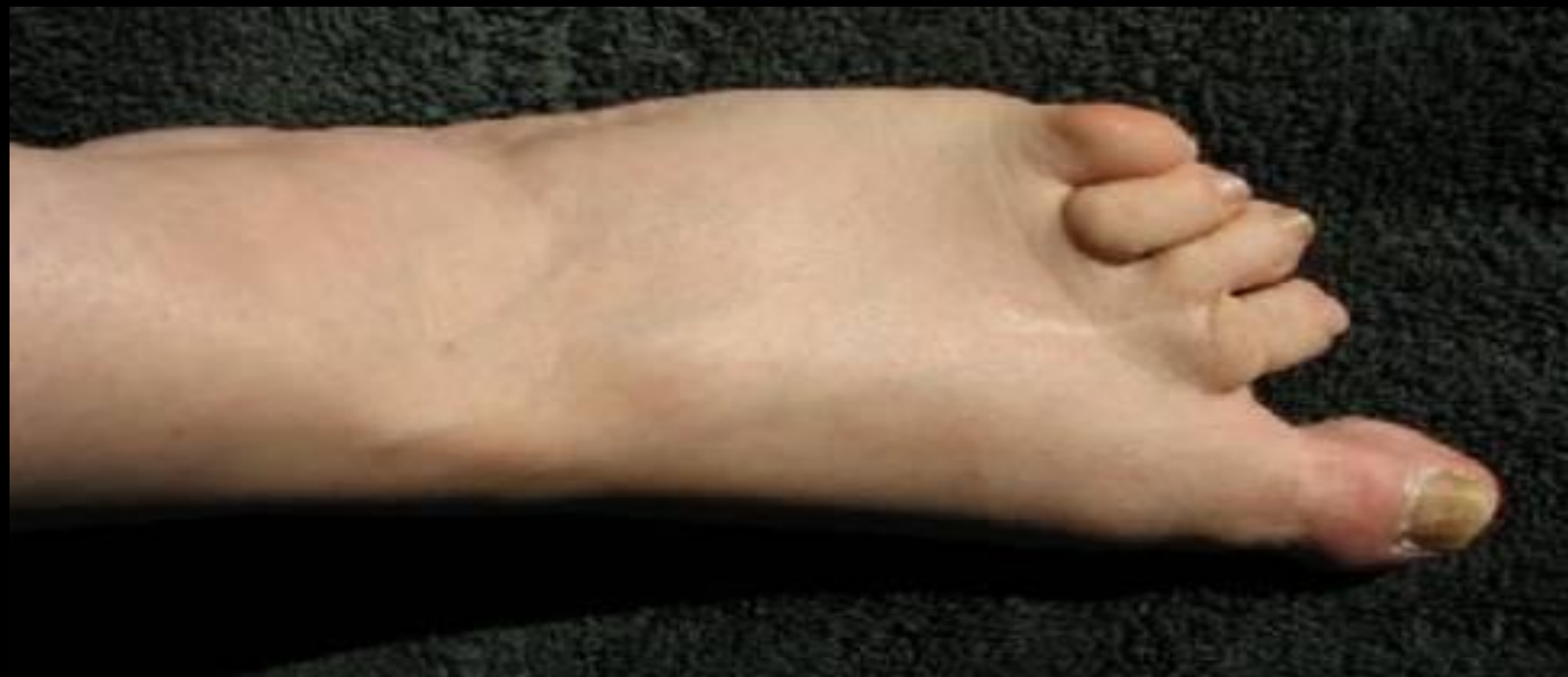











Exercises

- Arthritis Foundation has several designed programs
- Regular exercise for maintaining joint mobility and muscle strengthening
- Walking
- Water exercises

Nutritional Supplements

- Omega 3 fish oils
- Vitamin D
- Vitamin C
- Vitamin E
 - Must be watched if patient is on blood thinners
- Selenium
- Glucosamine

Other Considerations

- Weather
- Depression
- Clothing
- Meditation
- Yoga
- Acupuncture
- Arthritis Today



Drs. Joseph Howe, Terry Yochum and Gary Guebert



Drs. Terry Yochum, Joseph Howe and Norman "Norm" Kettner