

10th Annual Howe Oration May 25, 2017

Terry R. Yochum DC, DACBR, Fellow-ACCR
Denver, CO



Active and Inactive Spondylolysis at L5

16yo Soccer Player

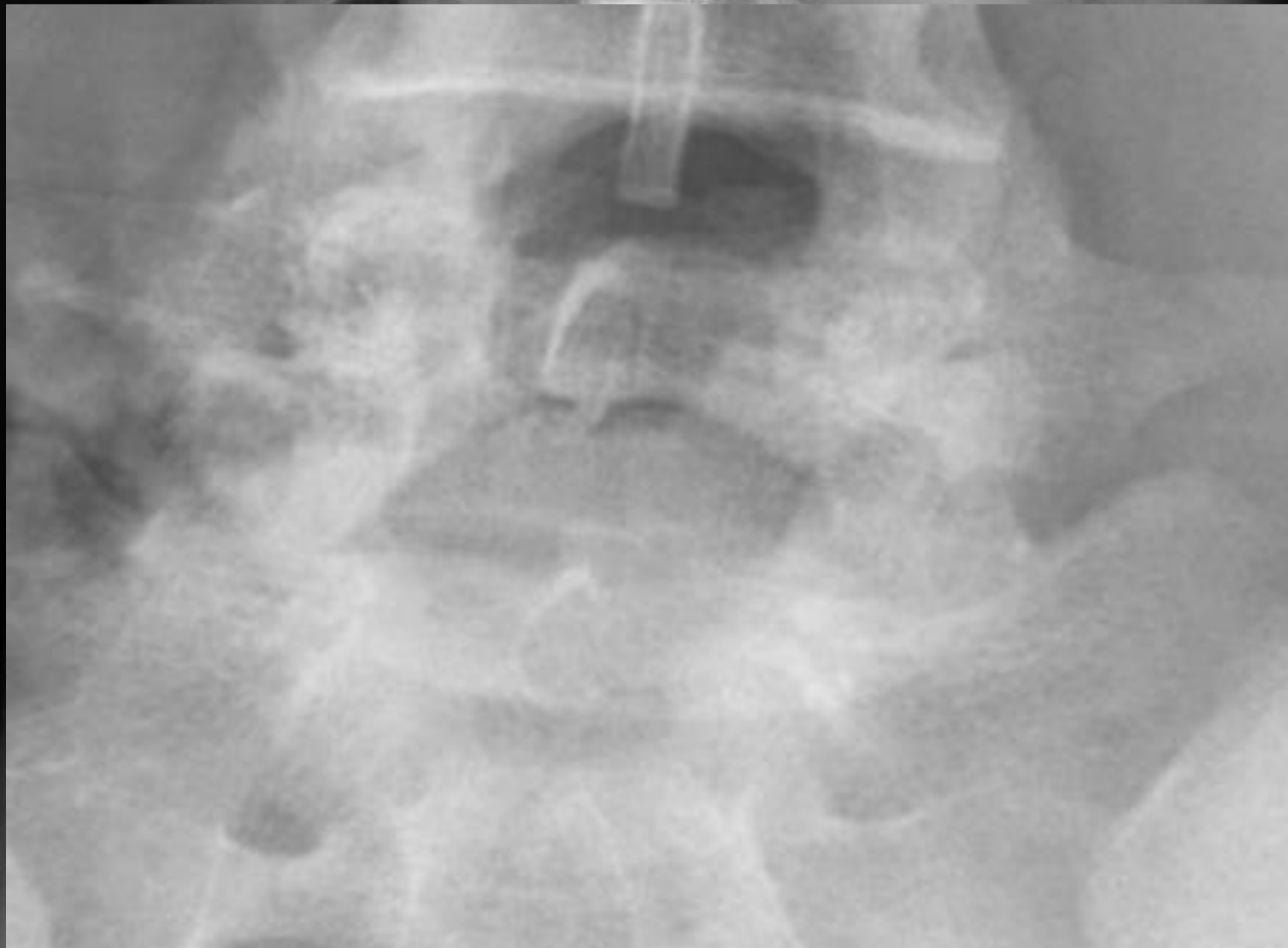
Right sided low back pain on extension and while kicking

Treated approximately 7x's without relief

Lumbar spine and pelvis radiography preformed

Case Courtesy of Peggy Brown-Grantham, DC

Kansas City, KS

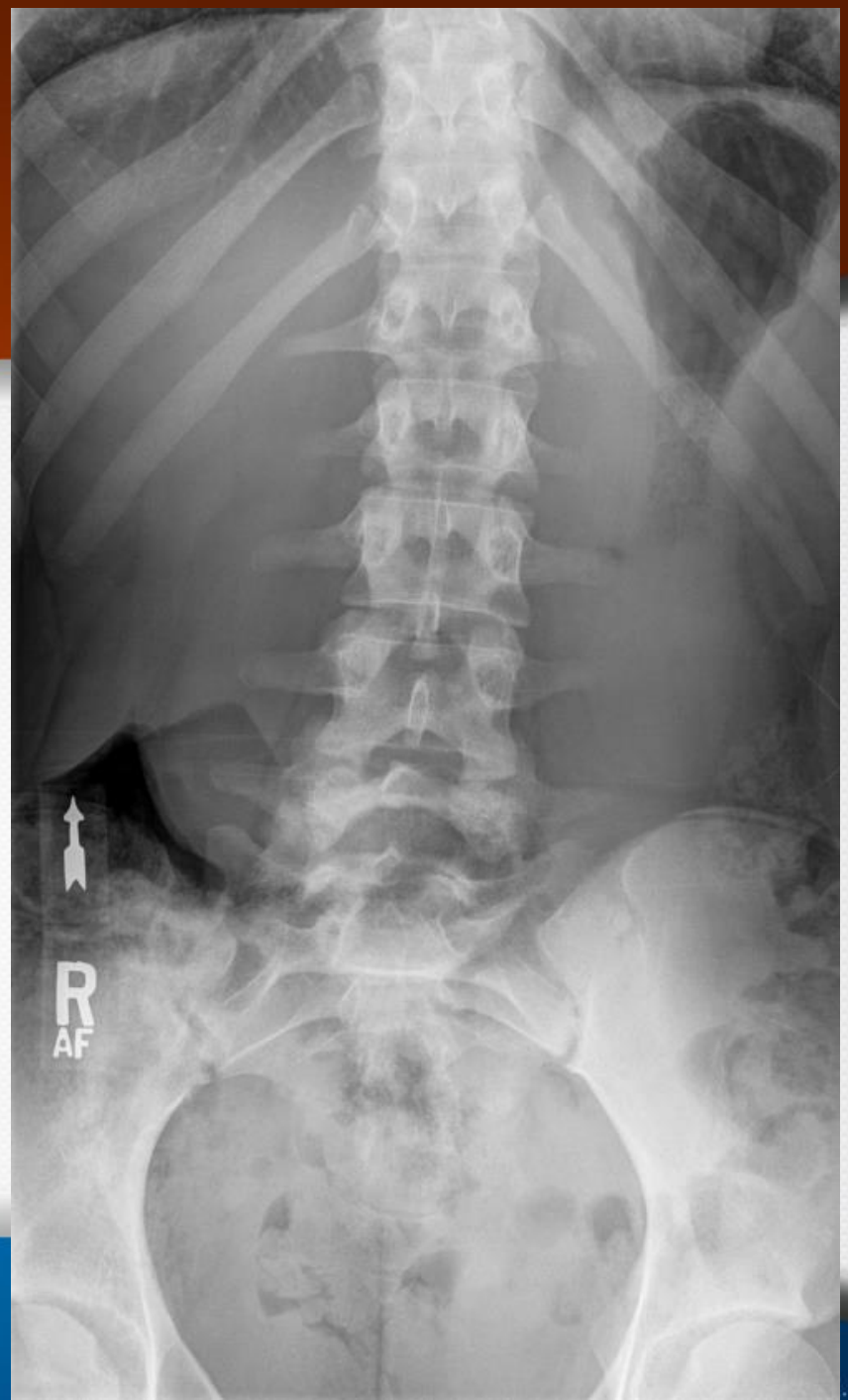
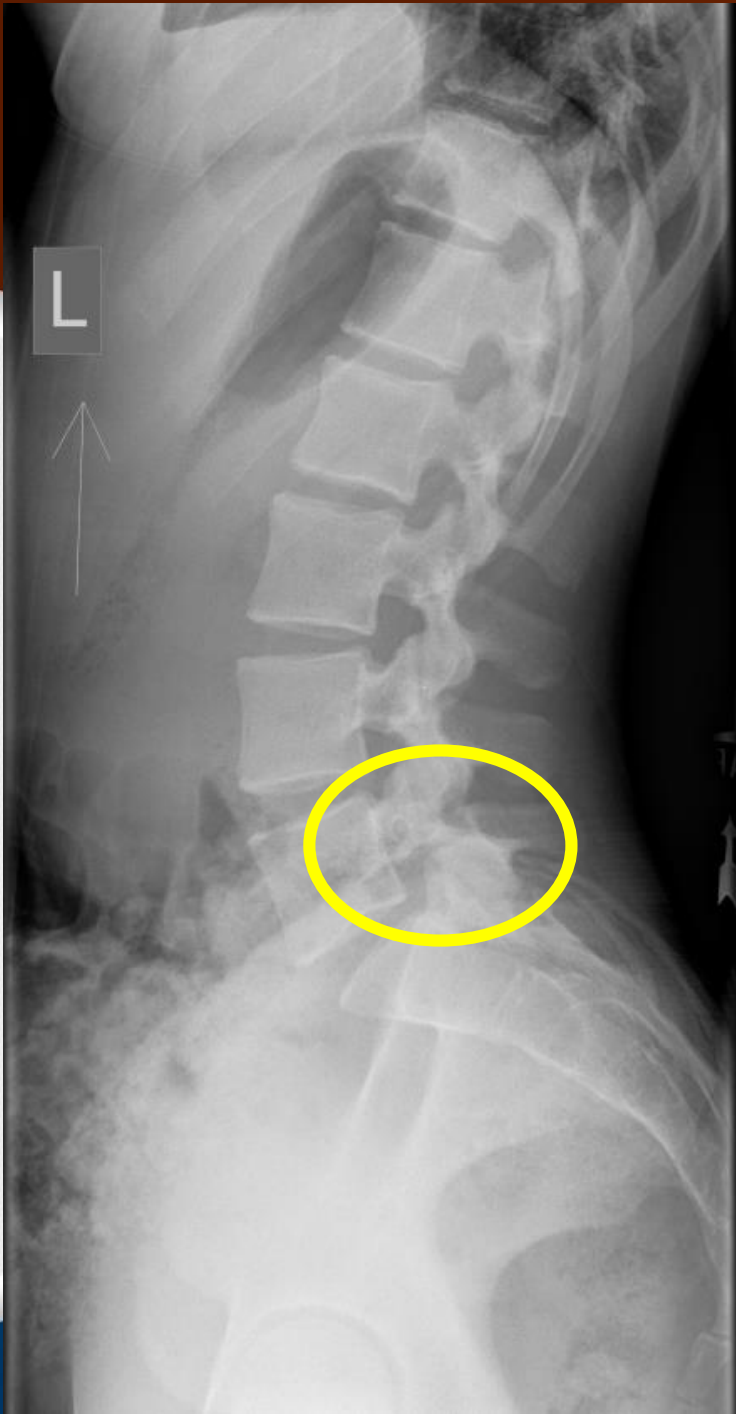
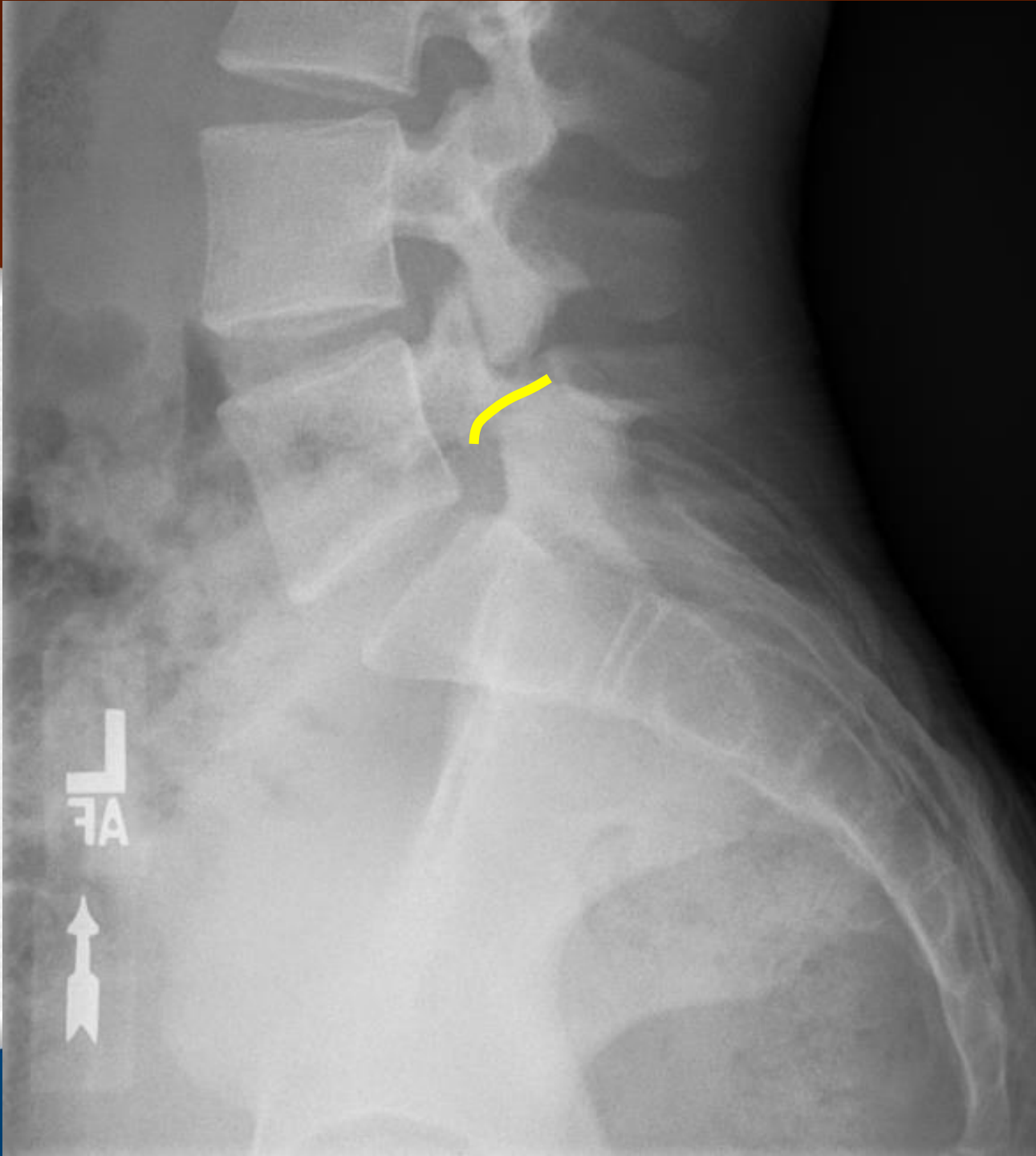
□

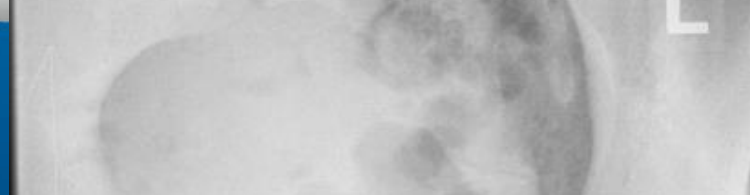
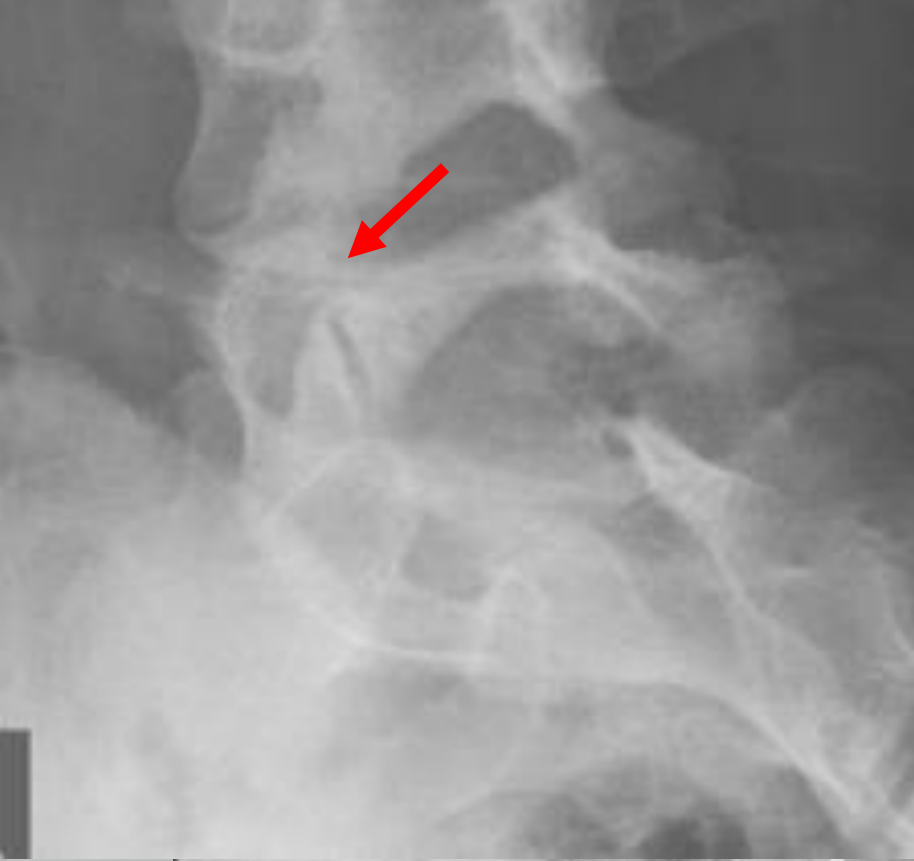
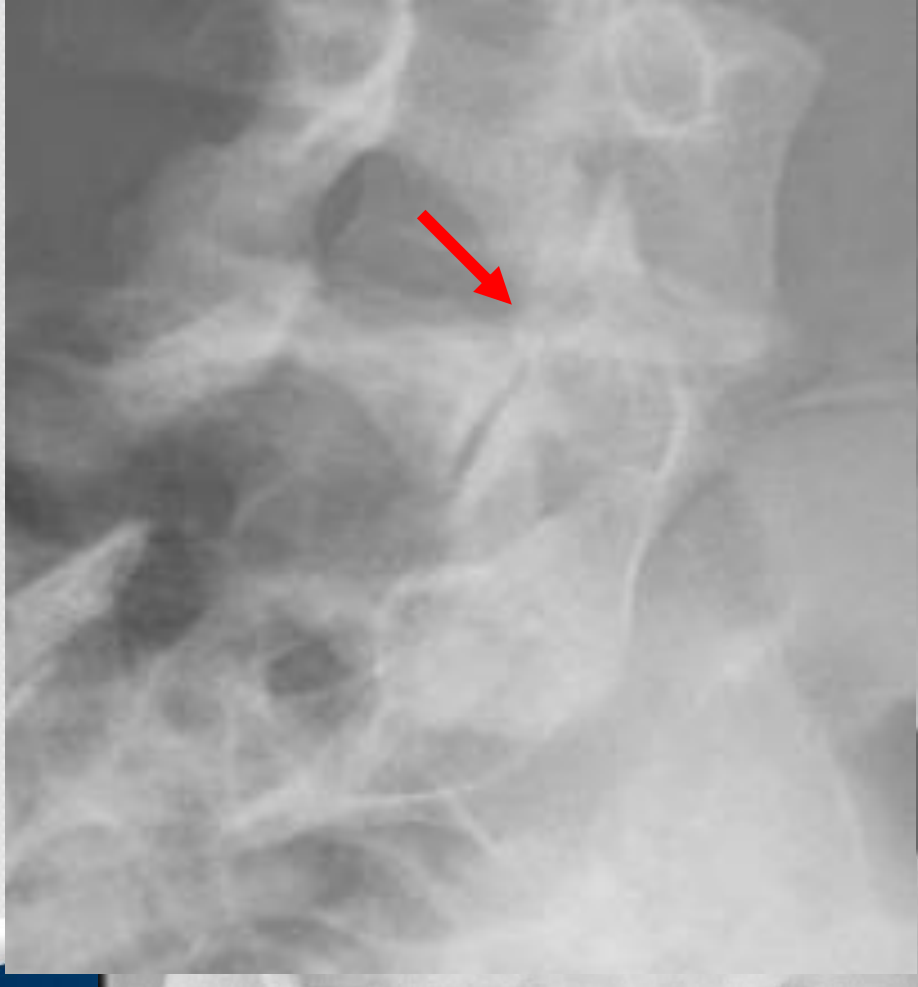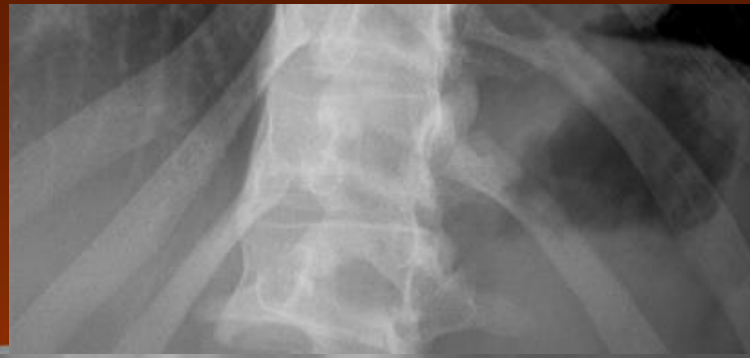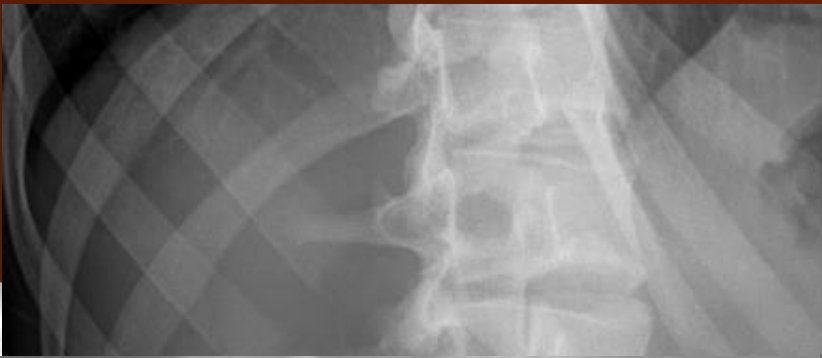R
AF

10cm

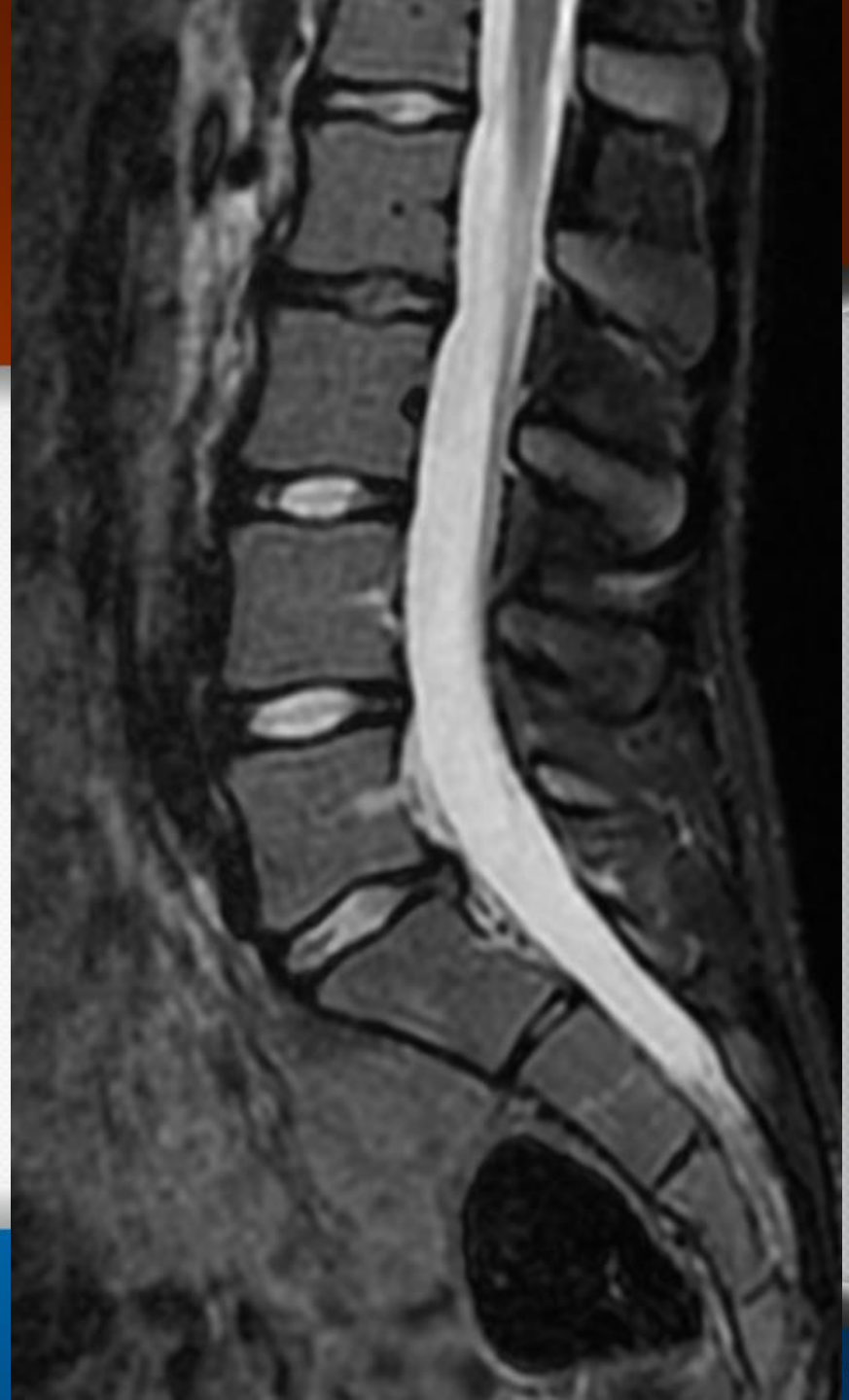





MRI- T2

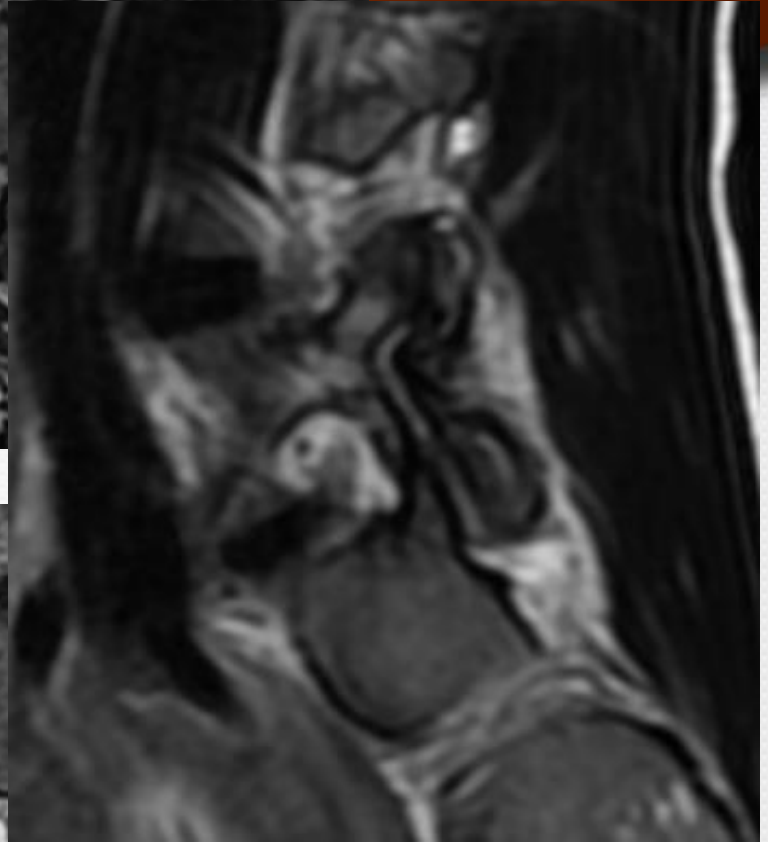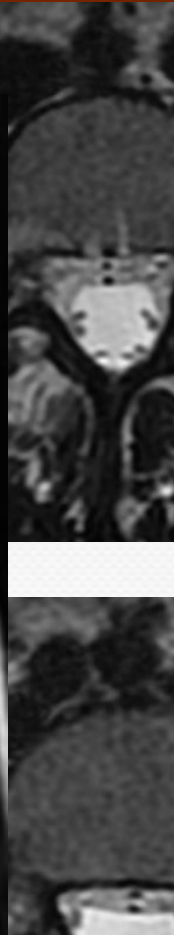
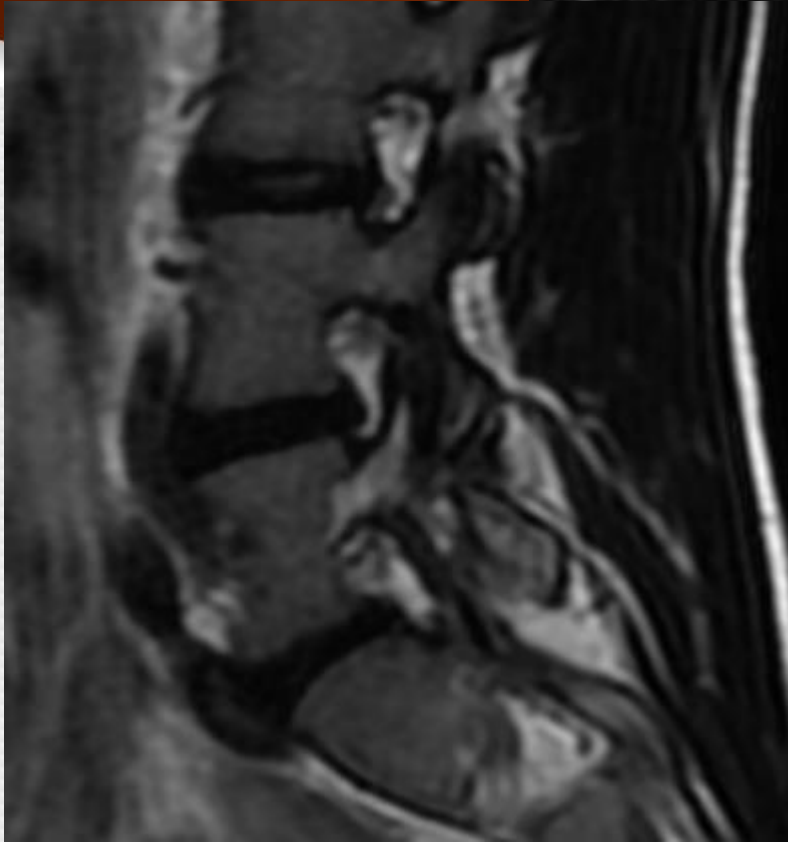- Failed trial of care
- MRI preformed
- Mid-Sagittal
- Normal Marrow



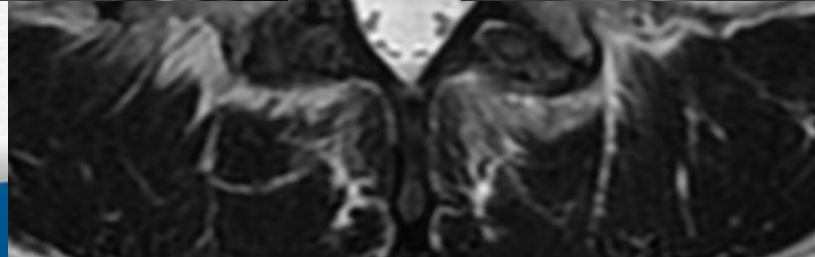
T2

RIGHT

LEFT



**Fat CAN appear
white on T2
Fast Spin Echo (FSE)**



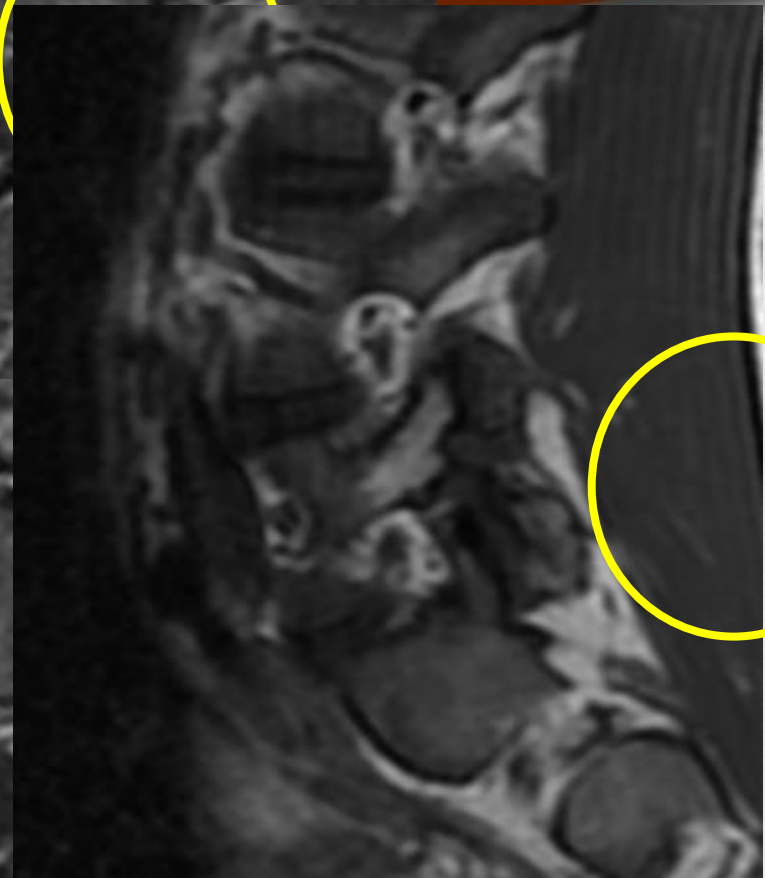
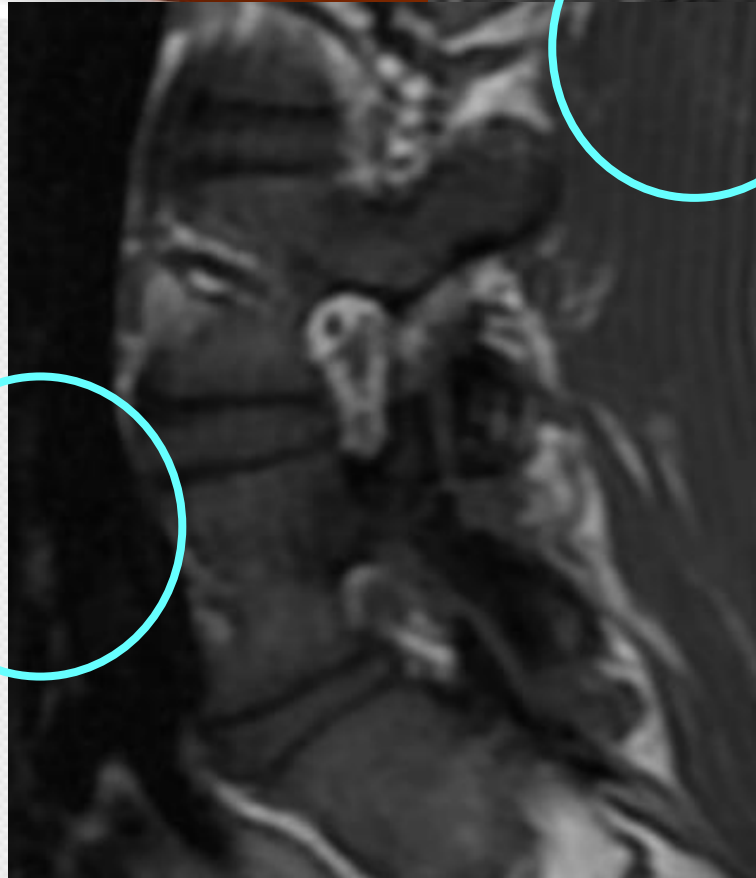
EDEMA/FLUID???

EDEMA

RIGHT

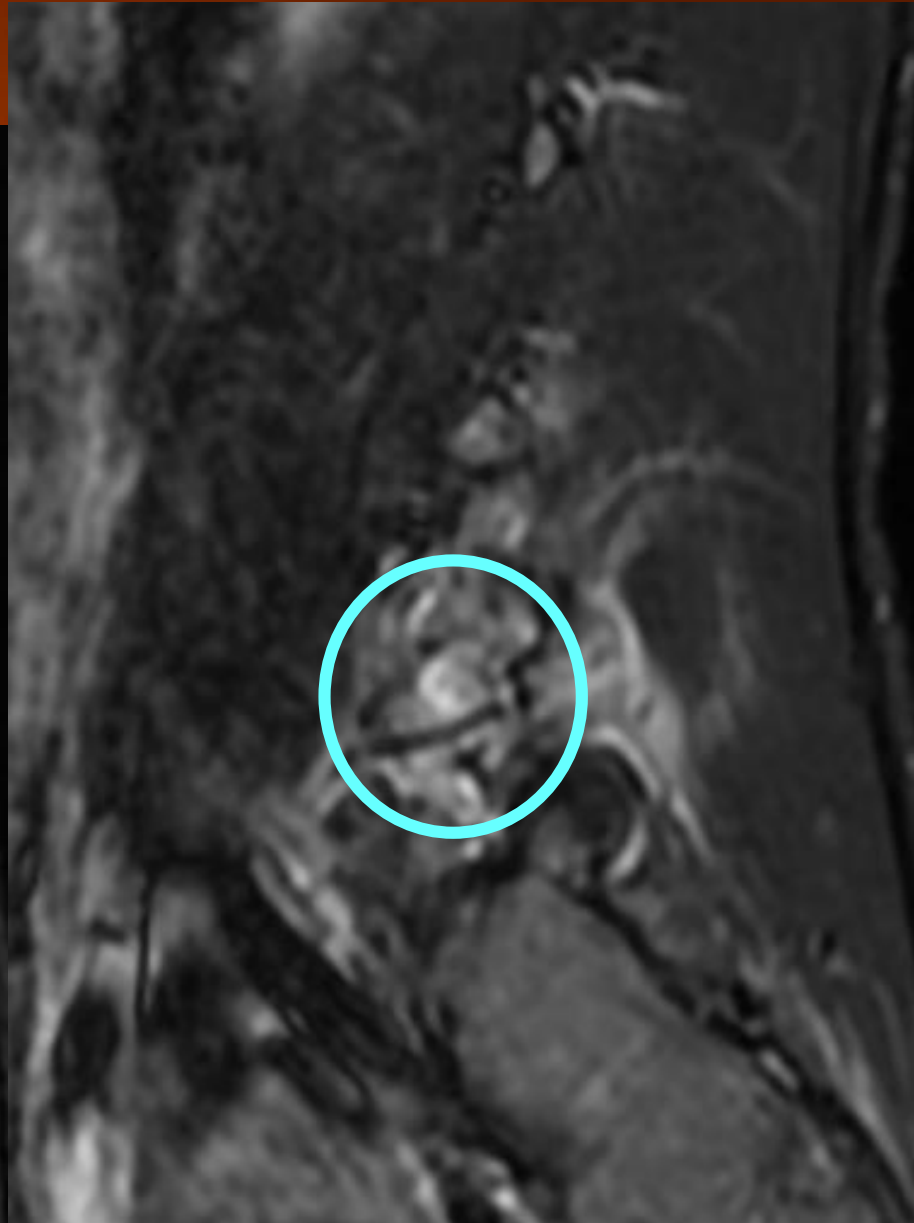
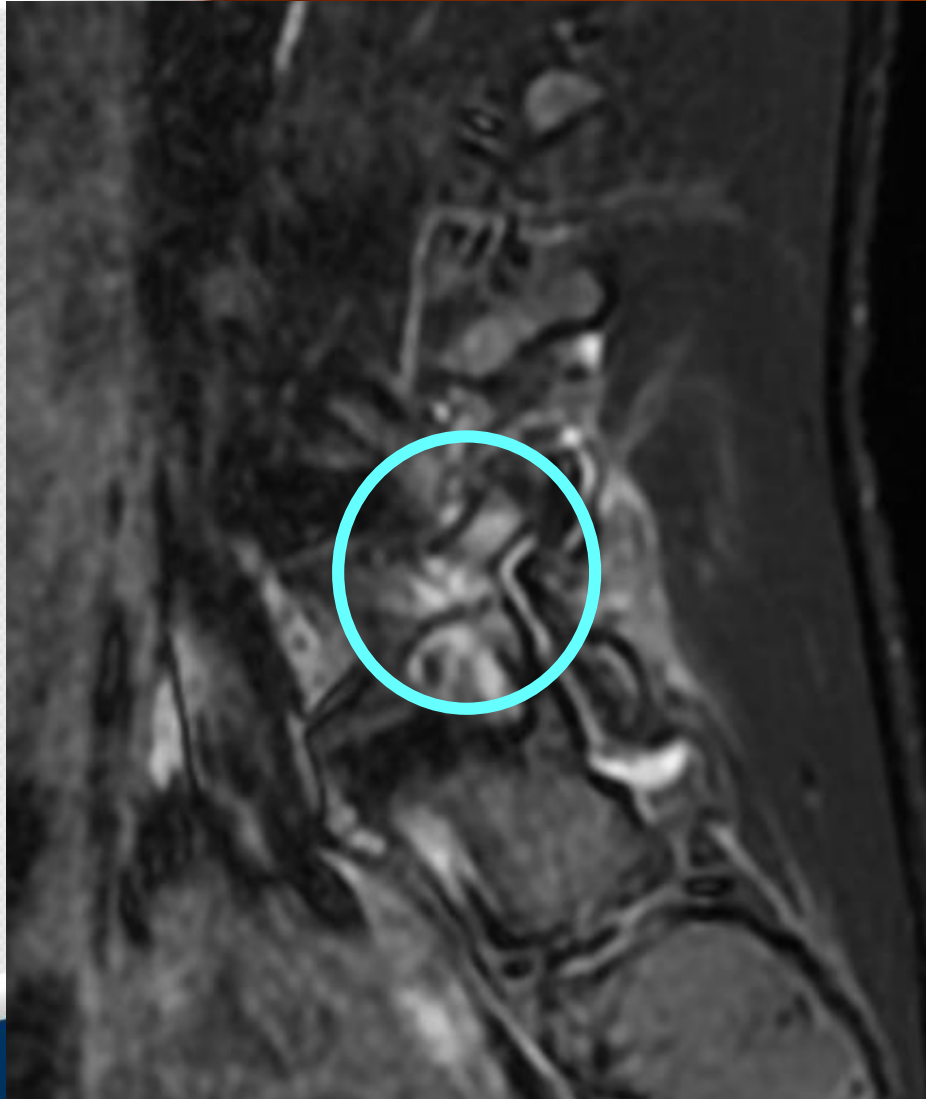
FAT

LEFT

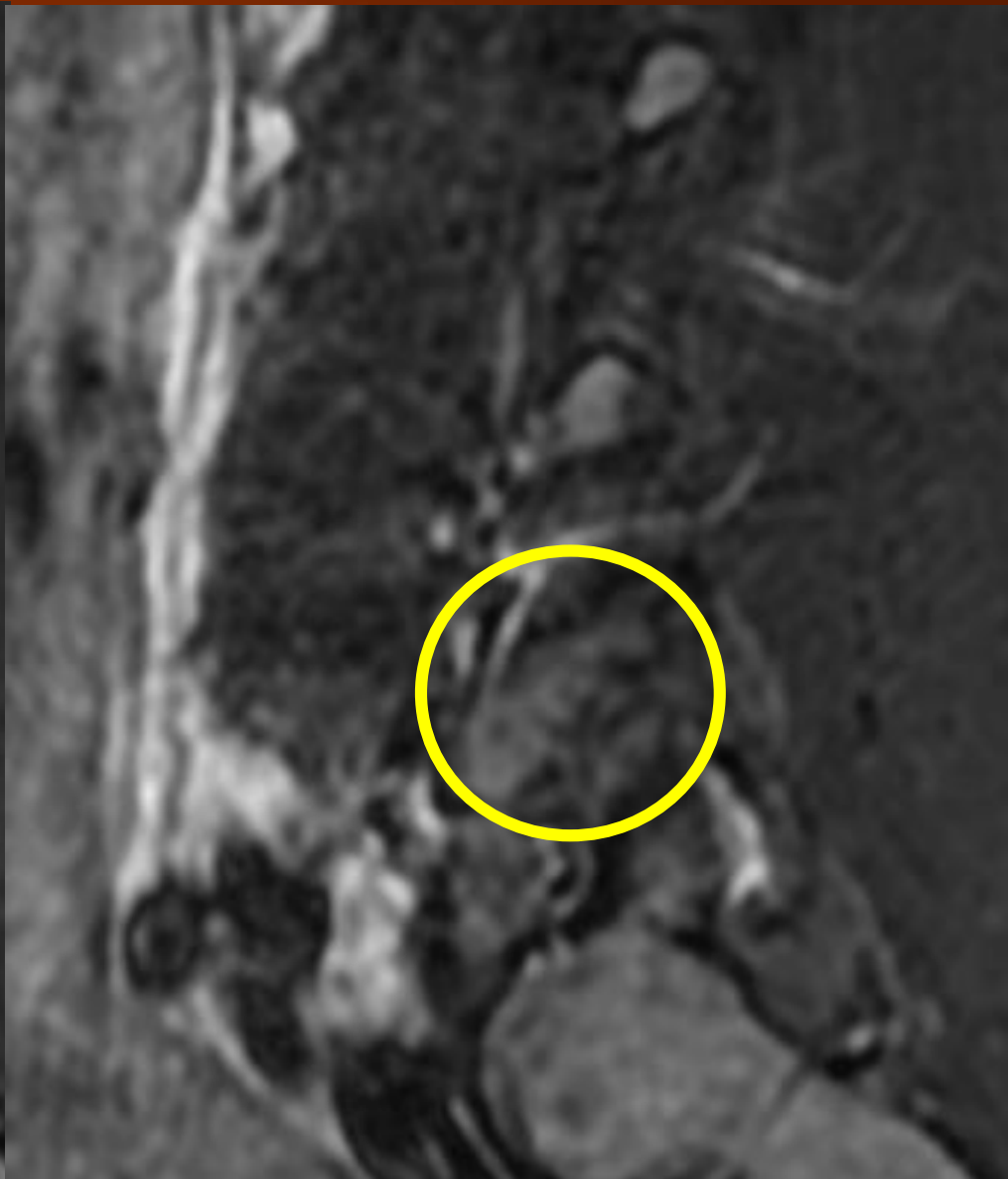
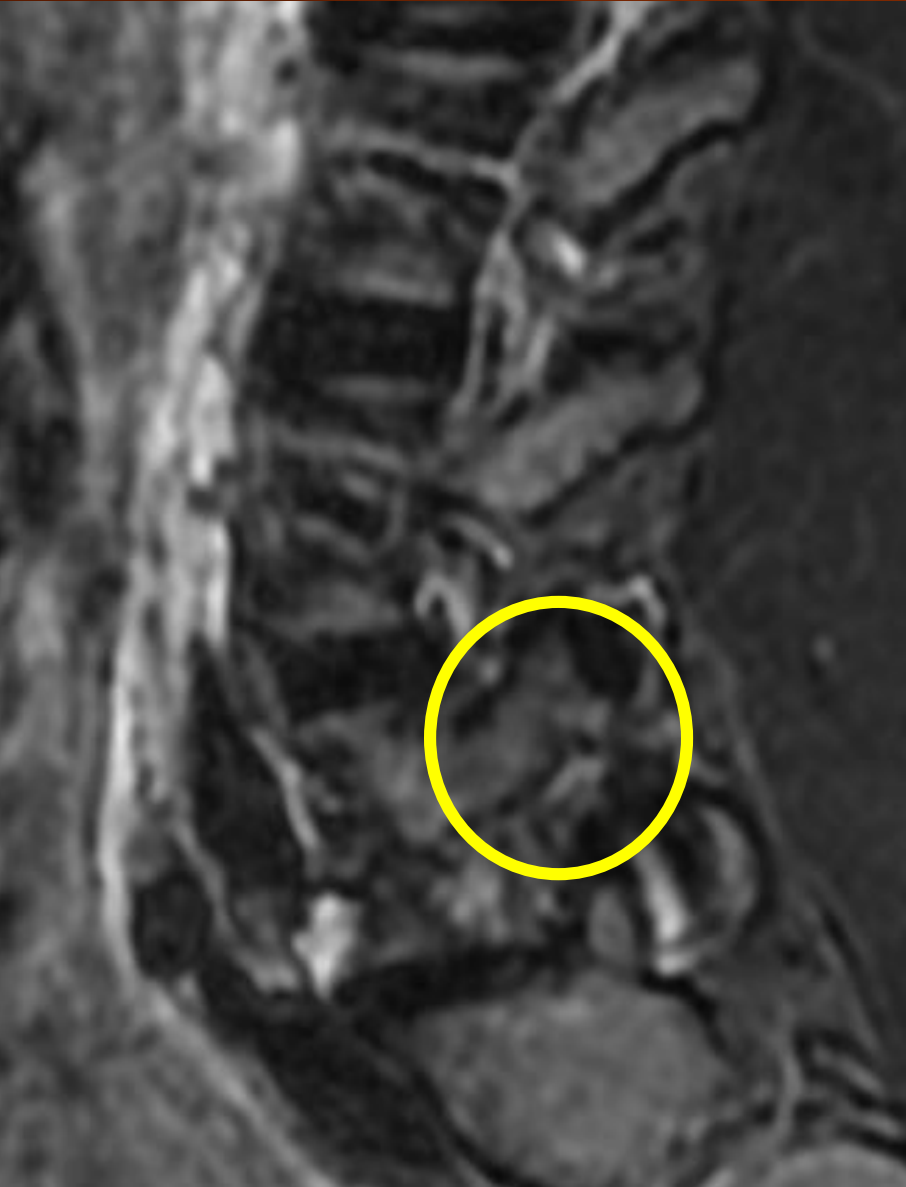

STIR: Fluid = Active Edema

RIGHT



STIR: NO Fluid = Inactive (Fat) LEFT

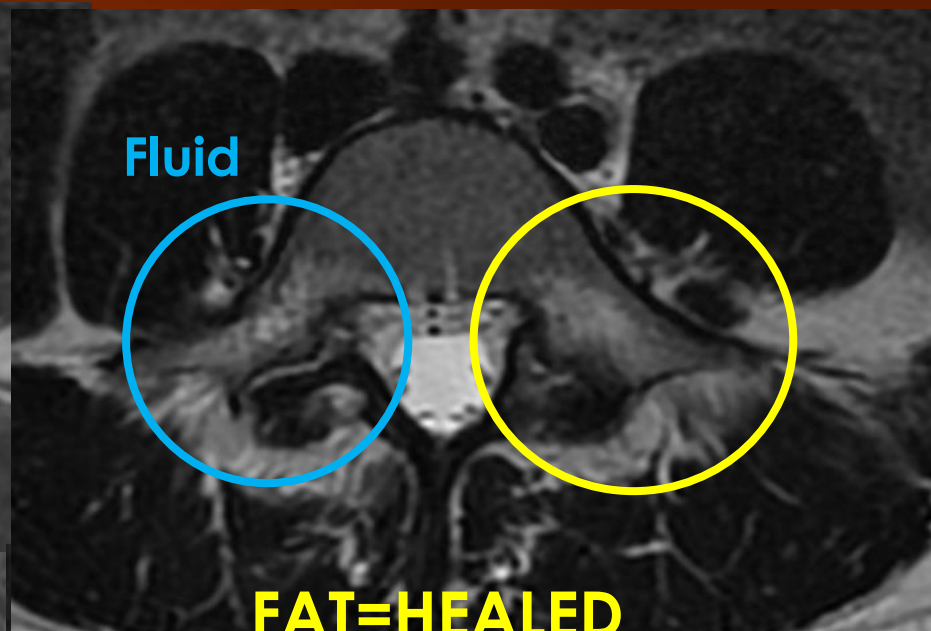
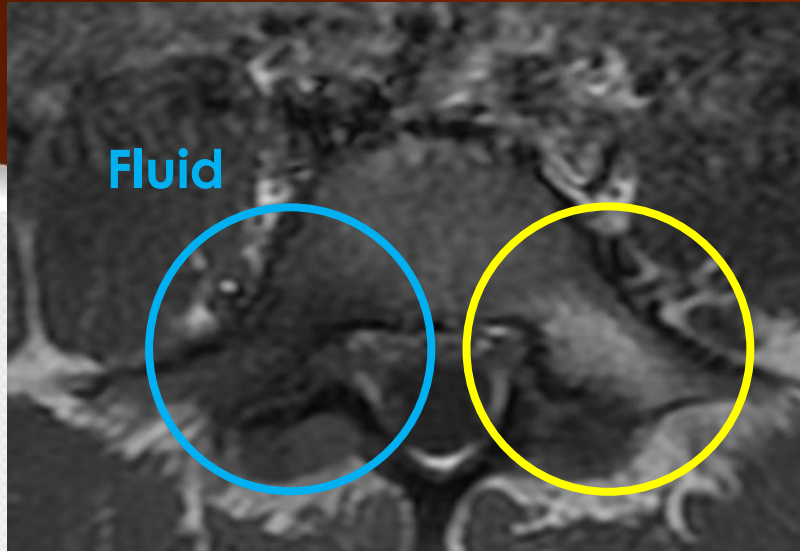


Patient placed in Boston Overlap
brace and taken out of active
participation in sports.

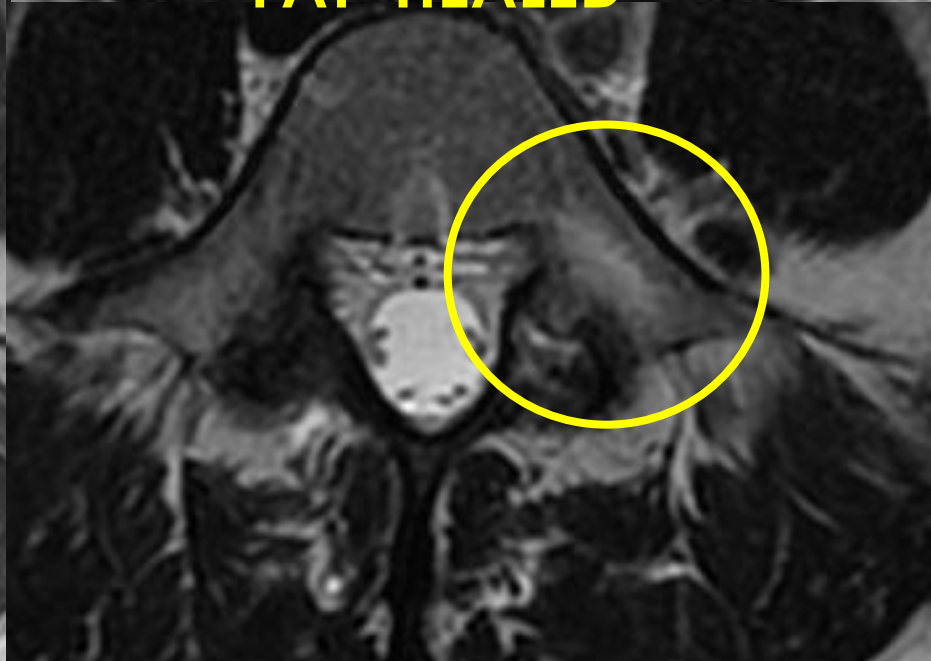
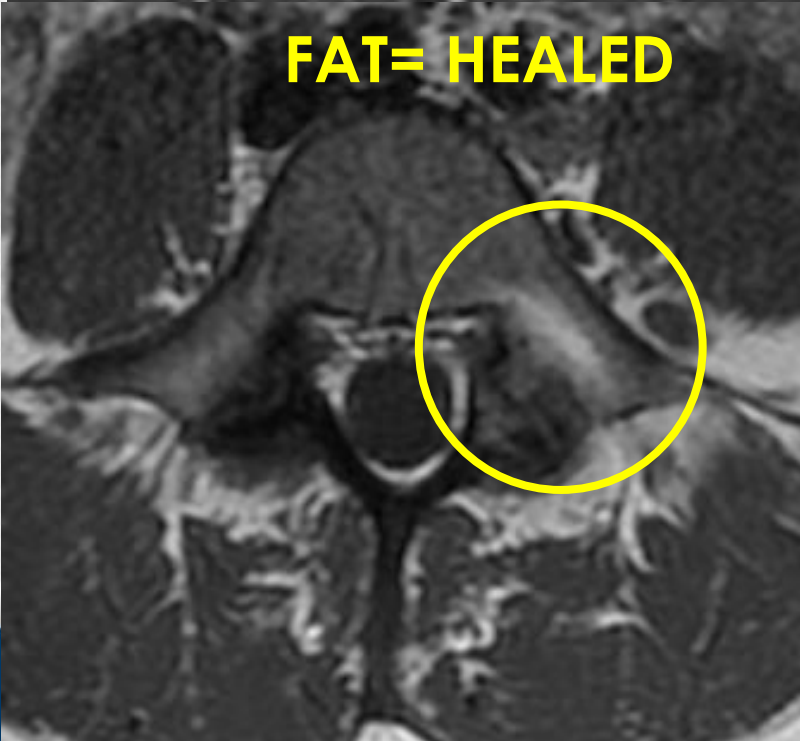
She was completely compliant

T1 4 Months-Follow up MRI T2

Pre



Follow



Right- Parasagittal= HEALED

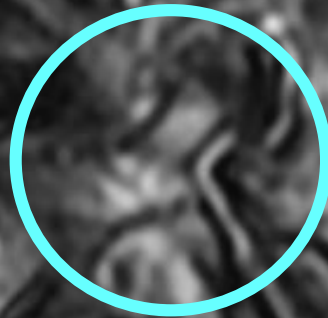FAT= INACTIVE

T1

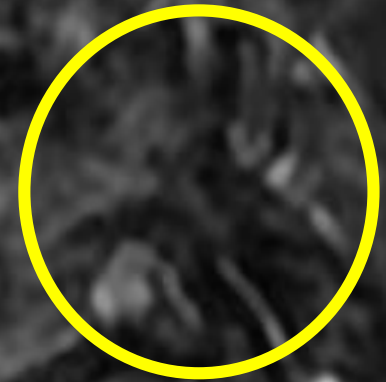
T2

STIR

Initial STIR
FLUID




FAT



Thank You!



Alicia M. Yochum RN,DC, DACBR, RMSK



Joseph W. Howe, D.C., D.A.C.B.R.